COLUMBIA LIBRARIES OFFSITE
HEALTH SCIENCES STANDARD
HX00035963

TRANSVESICAL PROSTATECTOMY IN TWO STAGES

PAUL MONROE PILCHER

ring wide open. That this frequently occurs is well shown by many specimens. However, it is hard to accept the theory that in some cases, or in many cases, the enlargement of the median lobe takes place in the direction of the lateral lobes, displacing them and causing atrophy of these lobes, compressing them out into a shell-like capsule; to produce a lateral extension of an adenoma of the median lobe, the expansion must take place, not along the avenue of least resistance, but against a firm, well-developed structure. Judging from the anatomical relations as found on the operating table, Tandler's conclusions as to the part of the prostate involved in the obstruction are incorrect.

Fig. 1 is an illustration taken from the work of Tandler and Zuckerkandl, showing a sagittal section through the pelvis in a case of prostatic hypertrophy. We agree that this represents a typical case of median lobe enlargement. A number of other illustrations which are shown in the work of Tandler and Zuckerkandl are unquestionably examples of median lobe enlargement, for in each the adenomatous mass is more or less symmetrical in the median line and is forced through the sphincter dilating it. The same phenomenon has been plainly shown in many of our own specimens, for example, Figs. 2, 3, and 4. At the same time, the enlargement of the lateral lobes without the median lobe enlargement may take place, and in such cases the sphincter is greatly dilated and surrounds the hypertrophied mass. Such a case is seen in Fig. 5. In this case the lateral lobes have become enormously hypertrophied and have carried the median lobe, which is also enlarged, through the sphincter well into the bladder. It cannot be conceived that, after the enucleation which was accomplished in this case, any prostatic tissue was left behind unless it was the posterior lobe which is so nearly independent. Fig. 6, however, shows a different condition. This was a case of complete urinary obstruction, which had lasted for three years. *B'*, *B'* are the adenomatous lateral lobes. *B* is a greatly hypertrophied median lobe. *A* is a crescent-shaped calculus, and the remaining pieces of tissue are compressed and atrophied bits of prostatic tissue which still

remained imbedded in the capsule of the prostate after the adenoma had been enucleated. Fig. 7 is an example of symmetrical enlargement of the median and both lateral lobes. Fig. 8 is an example of bilateral hypertrophy without any median lobe enlargement. The specimen is very distinct and convincing on this point. Fig. 9 is another example of irregular hypertrophy of the lateral lobe with very little median lobe enlargement. Fig. 10 shows a specimen removed in one piece in which the median lobe is enlarged and has pushed forward into the bladder and distorts the urethra, lifting it up and mak-

FIG. 4.

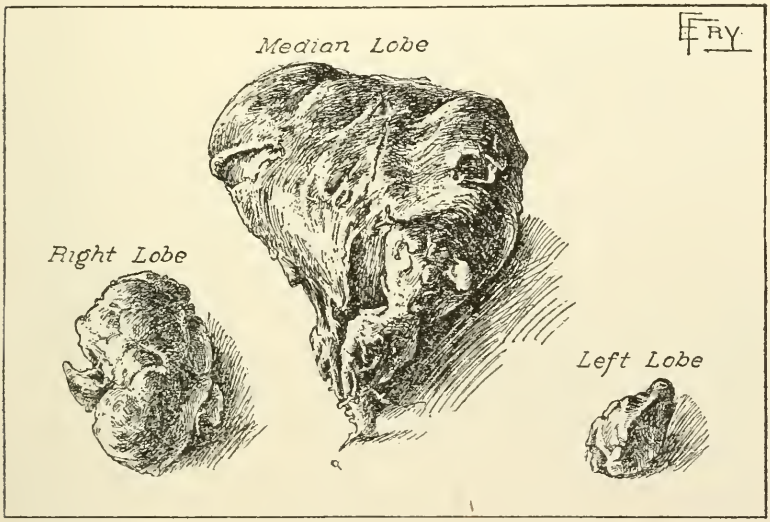

Drawing showing the three lobes of the prostate separated. Same specimen as Fig. 3.

ing it almost impossible to empty the bladder. The position of the sphincter is indicated by the arrows. Fig. 11 shows still another type of development. The lateral lobes in this case had been previously removed by perineal operation. The symptoms persisted and three years later this median lobe enlargement, with a very freely movable ball valve attachment, was taken out by a transvesical operation. No remnants of the lateral lobes could be found. It is interesting to note the position of the internal sphincter as indicated by the arrows.

RD587 P64

Columbia University
in the City of New York

College of Physicians and Surgeons

Library

Digitized by the Internet Archive
in 2010 with funding from
Open Knowledge Commons

http://www.archive.org/details/transvesicalpros00pilc

TRANSVESICAL PROSTATECTOMY IN TWO STAGES

WITH REMARKS UPON THE PATHOLOGY AND CLINICAL PHASES OF PROSTATIC OBSTRUCTION

BY

PAUL MONROE PILCHER, A.M., M.D.
PILCHER PRIVATE HOSPITAL
OF BROOKLYN—NEW YORK

J. B. LIPPINCOTT COMPANY
PHILADELPHIA & LONDON
1914

RD587
P64

Reprinted From
ANNALS OF SURGERY
April, 1914

TRANSVESICAL PROSTATECTOMY IN TWO STAGES.

BY PAUL MONROE PILCHER, M.D.,

OF BROOKLYN, NEW YORK.

I. THE PATHOLOGY OF CHRONIC PROSTATIC OBSTRUCTION. II. CONDITION INFLUENCING THE CHOICE OF TREATMENT-METHODS. III. THE THREE PHASES OF INTERRELATION BETWEEN OBSTRUCTION AT THE VESICAL OUTLET AND RENAL FUNCTION. IV. THE INDICATIONS FOR AND THE TECHNIC OF SUPRAPUBIC CYSTOSTOMY. V. TECHNIC OF TRANSVESICAL PROSTATECTOMY.

INTRODUCTION.

SINCE we have adopted the transvesical operation for the relief of urinary obstruction due to changes in the prostate, we have been able more fully to study the so-called living pathology of the condition inasmuch as the vesical outlet can be studied with the prostate *in situ,* the nature of the obstructing mass determined and the resultant deformities of the bladder studied. The removal of prostates in one piece in many cases and the interurethral enucleation in others has provided us with new material for extending our observations concerning the gross pathology of the disease.

Studying this last series of cases we are led to disagree with some of the more recently advanced theories concerning the pathology of the disease. In presenting this subject, therefore, we first offer our observations on the points in question. We do not reiterate much of the work which has already been published by Dr. Lewis S. Pilcher and myself.[1]

---

[1] Pilcher, Lewis S.: Choice of Operative Method for Removal of the Hypertrophied Prostate. ANNALS OF SURGERY, 1905, xli, 565.

Observations Upon the Removal of the Prostate for the Cure of Prostatic Dysuria. *New York State Journal of Medicine,* June, 1906.

Urinary Obstruction from Prostatic Hypertrophy. *Year Book of the Pilcher Hospital,* 1911, i, p. 60.

Pilcher, Paul M.: Pathology and Etiology of Obstructive Hypertrophy and Atrophy of the Prostate Gland. ANNALS OF SURGERY, 1905, xli, 481.

Choice of Operation for the Relief of Prostatic Dysuria and the Pre-

I. THE GROSS PATHOLOGY OF PROSTATIC HYPERTROPHY.

Most of the recent articles dealing with prostatic hypertrophy have presented evidence and theories concerning the gross pathology of the prostate. The work of Tandler and Zuckerkandl (1) tended to show that all of our previous ideas of the gross pathology of prostatic hypertrophy were wrong. Lowsley (2) presented his study of a series of sections of the human prostate in its early developmental period, which were distinctly in contrast to the series presented by the Austrian scientists. Wilson and McGrath (3) presented their studies of over 400 specimens and agreed to a certain extent with the theories of Tandler and Zuckerkandl. Henry Wade (4) gives the results of his exhaustive study of prostatism and deals with the surgical anatomy and pathology of the operative treatment.

Our own observations have not satisfied us that these theories are absolutely demonstrated to the satisfaction of surgical pathologists. Lowsley agrees with the more advanced pathologists and recognizes five lobes in the prostatic mass. The middle lobe is quite independent of the others and its tubules are distinctly separated from the others. They are situated within the gland structure and are in relation with the floor of the urethra. The posterior lobe is situated furthest from the bladder and is almost an independent structure. It is further of interest to note that the tubules of the middle lobe lie side by side with those of the lateral lobes, but at no point do they intermingle. The lateral lobes are made up of a series of tubules on each side of the urethra and the acini of these lobes form the main mass of the gland. It is distinctly indicated that the lateral lobes are in direct relation with the urethra. The posterior lobe seems to be almost an independent structure and is seldom involved in hypertrophy of the gland. It, how-

liminary Treatment Indicated. *Journal of the Michigan State Medical Society*, January, 1912.

The Suprapubic Two-step Operation for the Removal of the Hypertrophied Prostate. *American Journal of Surgery*, June, 1912.

The Operative Relief of Obstructive Hypertrophy of the Prostate *Journal of the Michigan State Medical Society*, September, 1913.

FIG. 1.

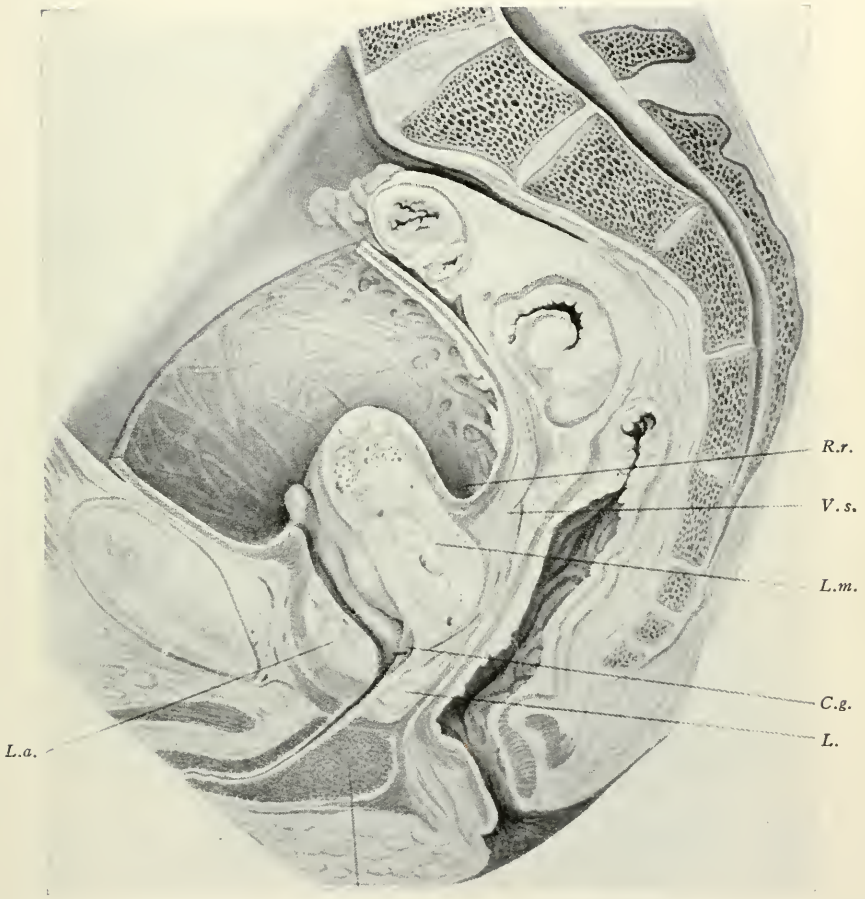

Sagitta section through the pelvis, showing the prostate hypertrophied. *B.u.*, bulbus urethralis; *C.g.*, caput gallinaginis; *L.a.*, lobus anterior; *L.m.*, lobus medius; *R.r.*, recessus retrouretericus; *V.s.*, vesicula seminalis. A short probe projects from the ejaculatory duct. (Tandler and Zuckerkandl, verlag von Dr. Werner Klinkhardt, Leipzig. Wilson and McGrath.)

FIG. 2.

Prostatic mass removed by transvesical operation, rubber tube showing direction of urethra. Beneath the rubber tube is a greatly hypertrophied middle lobe. The lateral lobes are seen forming the sides and roof of the urethra, but are not in any way obstructive

FIG. 3.

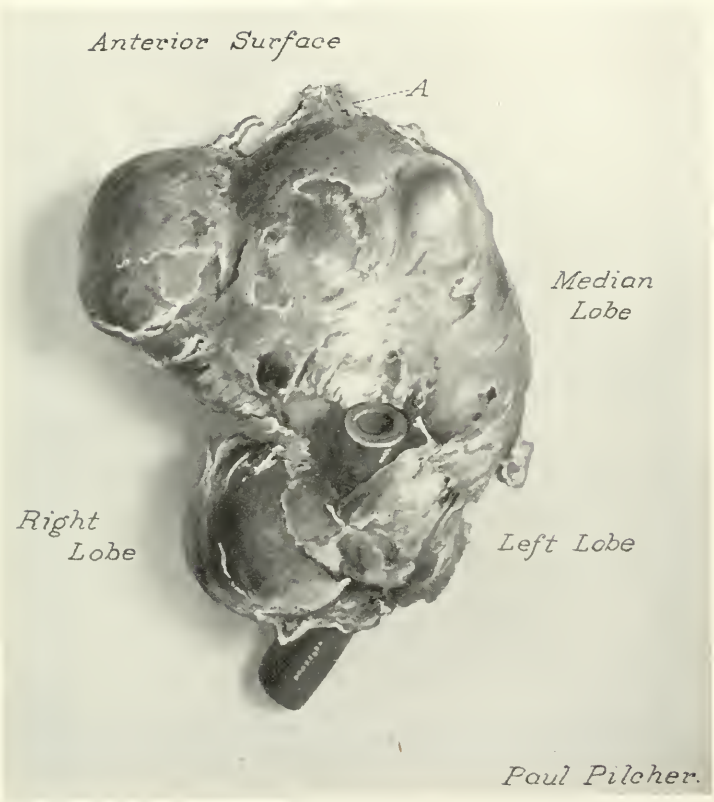

Enormous median lobe enlargement of the prostate with adenomatous changes in the lateral lobes. These lobes are smaller than normal and show no atrophy due to pressure. The specimen presents a view of the anterior face. The part above the rubber tube was entirely intravesical. The anterior face is covered by mucous membrane.

ever, seems to be a starting point for malignant degeneration in many cases. The subvesical accessory glands of Albarran, which develop on the surface of the median lobe, are not of much clinical importance in the experience of the writer.

As a result of our personal observations hereinafter detailed we believe:

1. That Tandler and Zuckerkandl are mistaken in their conclusions that prostatic hypertrophy is always a hypertrophy of the anatomical middle lobe.

2. That Tandler and Zuckerkandl are incorrect in assuming that the so-called prostatectomy does not in a great majority of cases mean practically total removal of the prostate. We appreciate that in some cases of irregularly developed prostatic adenomata some prostatic tissue becomes atrophied and compressed and forms a shell around the adenomatous mass and is not entirely removed at operation.

3. We question that the surgical capsule is formed only by compressed peripheral parts of the prostate.

4. We agree that the anatomical relations of the hypertrophied prostate to the sphincter vesicæ, the bladder itself and the ductus deferentes recommend the transvesical route as the one to be chosen in removing an enlarged prostate.

The first three of the conclusions advanced by the Austrians are so at variance with the accepted ideas of the pathology of the prostate in cases of obstructive hypertrophy, that the writer took occasion to visit Vienna and study the specimens which had been prepared by Professor Tandler and from which these conclusions were drawn. The writer spent some time in going over the question with Professor Tandler so that these observations are not based upon hearsay. Studying Tandler's specimens we accept his theory that the posterior lobe seldom hypertrophies. In other words, the enlargement takes place toward the bladder. However, in my mind the exhibits do not prove that the enlargement always involves the median lobe alone. If enlargement of the median lobe takes place, it must proceed along the avenue of least resistance, which is through the vesical outlet, gradually dilating it and forcing the sphincter

ring wide open. That this frequently occurs is well shown by many specimens. However, it is hard to accept the theory that in some cases, or in many cases, the enlargement of the median lobe takes place in the direction of the lateral lobes, displacing them and causing atrophy of these lobes, compressing them out into a shell-like capsule; to produce a lateral extension of an adenoma of the median lobe, the expansion must take place, not along the avenue of least resistance, but against a firm, well-developed structure. Judging from the anatomical relations as found on the operating table, Tandler's conclusions as to the part of the prostate involved in the obstruction are incorrect.

Fig. 1 is an illustration taken from the work of Tandler and Zuckerkandl, showing a sagittal section through the pelvis in a case of prostatic hypertrophy. We agree that this represents a typical case of median lobe enlargement. A number of other illustrations which are shown in the work of Tandler and Zuckerkandl are unquestionably examples of median lobe enlargement, for in each the adenomatous mass is more or less symmetrical in the median line and is forced through the sphincter dilating it. The same phenomenon has been plainly shown in many of our own specimens, for example, Figs. 2, 3, and 4. At the same time, the enlargement of the lateral lobes without the median lobe enlargement may take place, and in such cases the sphincter is greatly dilated and surrounds the hypertrophied mass. Such a case is seen in Fig. 5. In this case the lateral lobes have become enormously hypertrophied and have carried the median lobe, which is also enlarged, through the sphincter well into the bladder. It cannot be conceived that, after the enucleation which was accomplished in this case, any prostatic tissue was left behind unless it was the posterior lobe which is so nearly independent. Fig. 6, however, shows a different condition. This was a case of complete urinary obstruction, which had lasted for three years. *B'*, *B'* are the adenomatous lateral lobes. *B* is a greatly hypertrophied median lobe. *A* is a crescent-shaped calculus, and the remaining pieces of tissue are compressed and atrophied bits of prostatic tissue which still

remained imbedded in the capsule of the prostate after the adenoma had been enucleated. Fig. 7 is an example of symmetrical enlargement of the median and both lateral lobes. Fig. 8 is an example of bilateral hypertrophy without any median lobe enlargement. The specimen is very distinct and convincing on this point. Fig. 9 is another example of irregular hypertrophy of the lateral lobe with very little median lobe enlargement. Fig. 10 shows a specimen removed in one piece in which the median lobe is enlarged and has pushed forward into the bladder and distorts the urethra, lifting it up and mak-

FIG. 4.

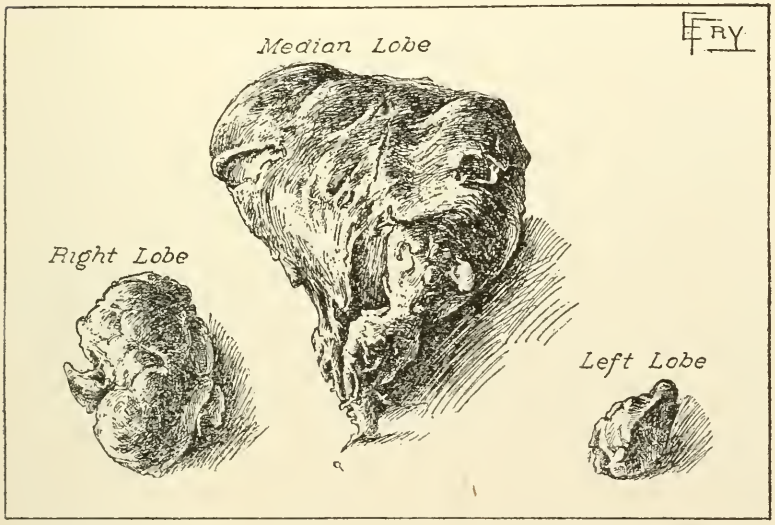

Drawing showing the three lobes of the prostate separated. Same specimen as Fig. 3.

ing it almost impossible to empty the bladder. The position of the sphincter is indicated by the arrows. Fig. 11 shows still another type of development. The lateral lobes in this case had been previously removed by perineal operation. The symptoms persisted and three years later this median lobe enlargement, with a very freely movable ball valve attachment, was taken out by a transvesical operation. No remnants of the lateral lobes could be found. It is interesting to note the position of the internal sphincter as indicated by the arrows.

In this case we had the obstruction of the enlarged mass and in addition a ball valve action.

Fig. 12 is the photograph of a specimen, actual size, removed in one piece. It is a perfect example of hypertrophy of both lateral lobes of the prostate. Fig. 13 shows a section through the centre of this mass and shows quite distinctly the three lobes, the two lateral lobes and the median lobe, and their position in relation to the urethra. The median lobe extends up like a wedge between the two lateral lobes and is only moderately enlarged. In this connection reference may be made to the series of photographs of specimens which were published in 1888 by Francis S. Watson, of Boston, in his treatise on the Operative Treatment of Hypertrophy of the Prostate. Plate 4 (reproduced here as Fig. 14) shows a very important feature; the lateral lobes are moderately enlarged, the median lobe is distinctly enlarged and is projecting into the bladder, forming the cause of the obstruction. Distal to the median lobe enlargement is seen a raised-up portion, which is the colliculus or verumontanum, at which point the vasa deferentia empty into the urethra. If the finger is introduced into the urethra by the transvesical route in enucleating the prostate, one can easily see from the specimen how the colliculus may be preserved. Fig. 15 is an undeniable example of hypertrophy of both the lateral and median lobes of the prostate. This specimen, which is a dissection not only of the prostate but of the bladder as well, shows exactly the relation which no drawing could so well express. Fig. 16 shows another phase which is a bilateral hypertrophy of the prostate with a slight median lobe development causing a distinct prostatic bar. The tortuous course of the urethra, the presence of the colliculus and its relative position are clearly shown. No one could argue that in these specimens such a hypertrophy originates from the median lobe alone. The floor of the urethra is very clearly shown and is seen to be free from all hypertrophied tissue. This portion of the urethra must invariably be involved, at least that portion between the colliculus and the sphincter, in all median lobe enlargements. Fig. 17 is a perfect example of median lobe enlargement alone.

FIG. 5.

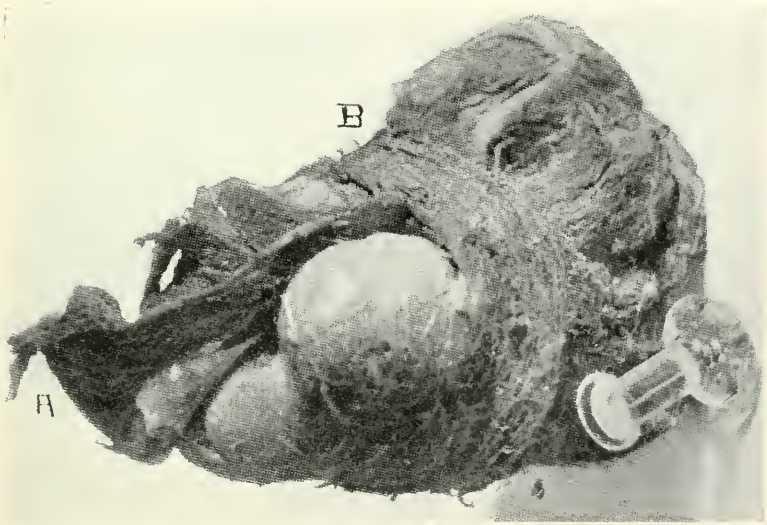

Photograph of hypertrophied prostate removed by suprapubic route. Showing bilateral and median enlargement. At vesical pole, *A*, the capsule and mucous membrane of the bladder are shown stripped back from the glandular portion of the gland. At *B* is seen the circular capsule which passes entirely around the gland.

FIG. 6.

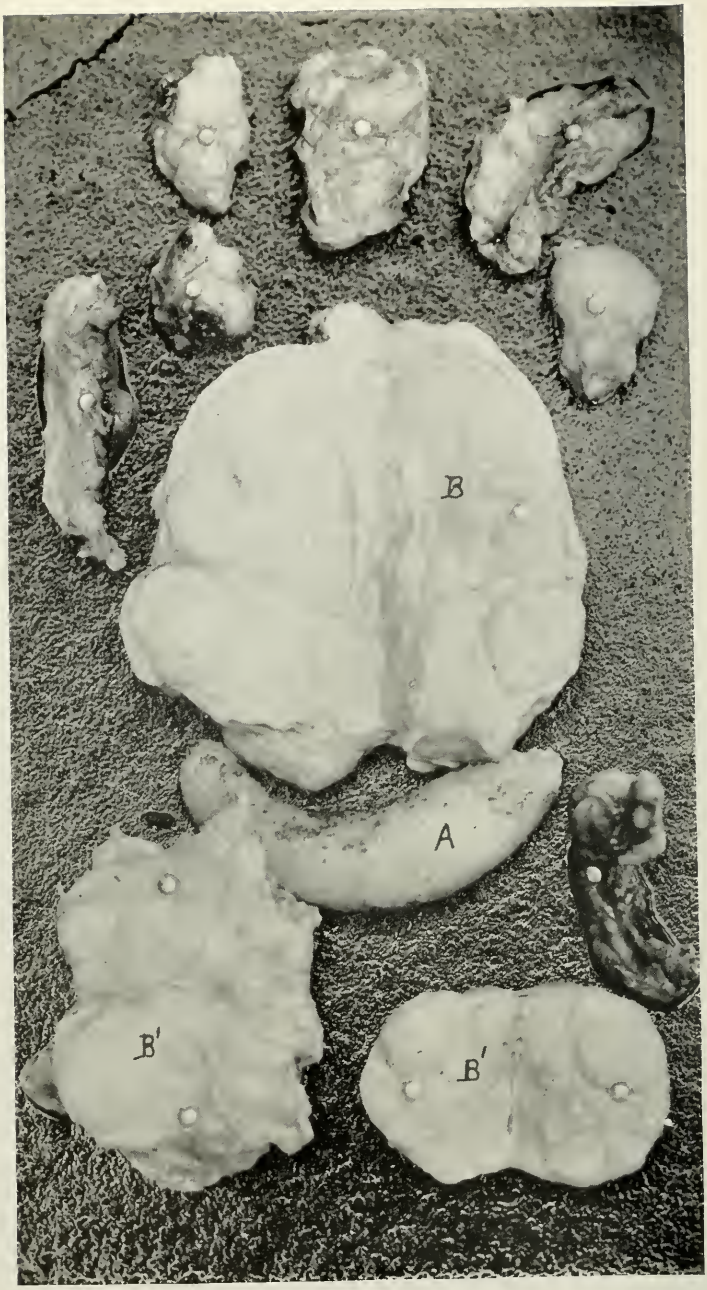

Photograph of prostatic masses removed by transvesical route. *A*, is a crescent-shaped calculus; *B*, a large median lobe; *B' B'*, the two lateral lobes. The other pieces of tissue shown in the specimen are atrophied prostatic tissue adherent to the capsule.

FIG. 7.

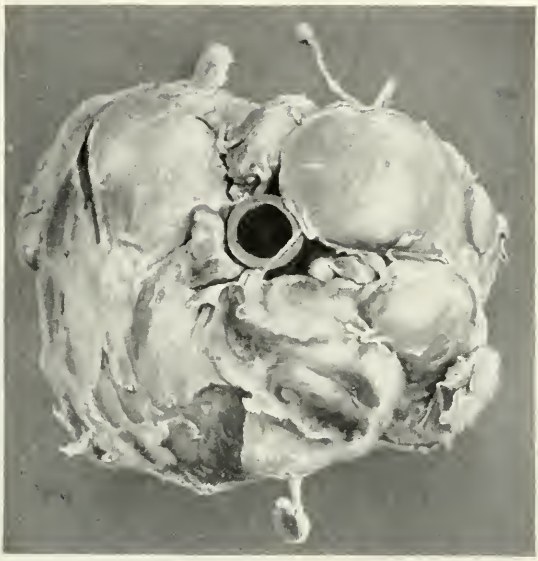

Specimen removed by transvesical operation showing symmetrical enlargement of both median and lateral lobes.

FIG. 8.

Specimen removed by transvesical operation showing hypertrophy of lateral lobes without involvement of median lobe.

Fig. 9.

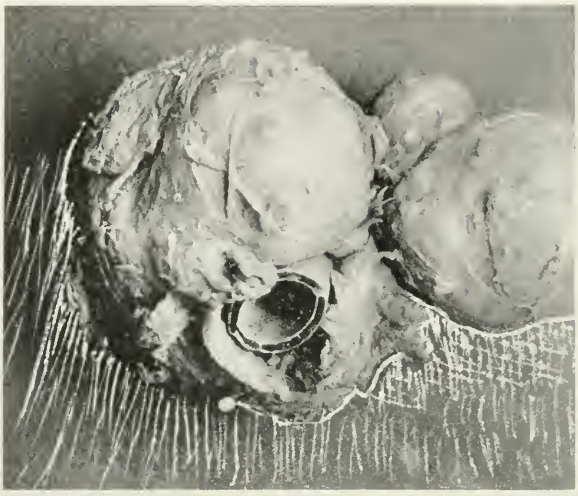

Specimen removed by transvesical operation showing irregular hypertrophy of the lateral lobes with very little median lobe enlargement.

Fig. 10.

Specimen removed by transvesical operation showing marked median lobe enlargement with practically no lateral lobe enlargement.

FIG. 11.

Median lobe enlargement with ball valve attachment.

FIG. 12.

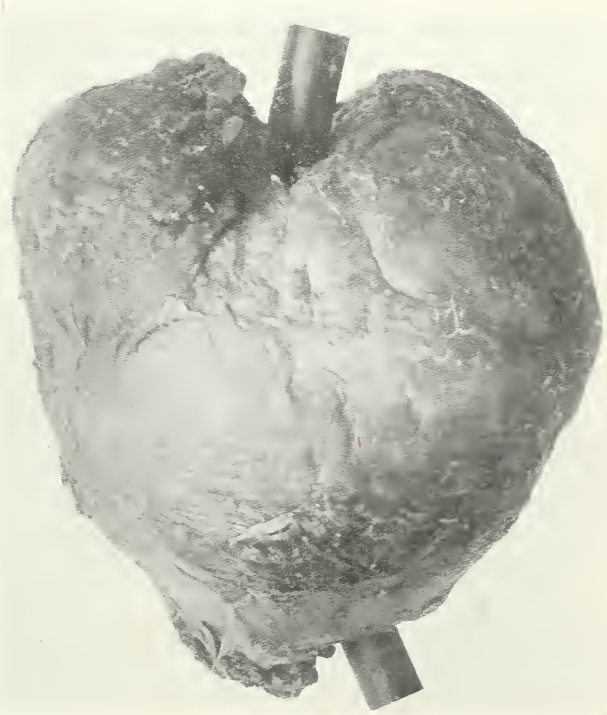

Enlargement of the prostate in which the two lateral lobes are involved. The vesical surface of the prostate appears at the top of the picture. This specimen was removed within its capsule and is a perfect example of coincident hypertrophy of both lateral lobes without any marked median lobe enlargement. The section through this mass is seen in the following figure which shows the narrow cleft occupied by the urethra. The two lateral masses and the small adenomatous median lobe are seen.

Fig. 13.

Cross section of specimen shown in Fig. 12 showing relation of median lobe and two lateral lobes to the urethra.

FIG. 14.

Bilateral and median lobe hypertrophy of prostate. Position of colliculus. This photograph shows the exact relation of the urethra, hypertrophied prostate and bladder as an example of moderate bilateral hypertrophy of the prostate, with median lobe enlarged and projecting into the bladder, the median lobe forming the chief obstruction. Following the urethra upward from the bladder, it will be seen that the urethra inclines sharply downward due to the bulging of the median lobe, which forms the floor of the urethra as far forward as the colliculus. If the finger were introduced into the urethra through the bladder, it can be easily seen from this picture how the entire prostate could be removed without injury to the colliculus. (Reproduced from Francis S. Watson's work on The Operative Treatment of the Hypertrophied Prostate.)

FIG. 15.

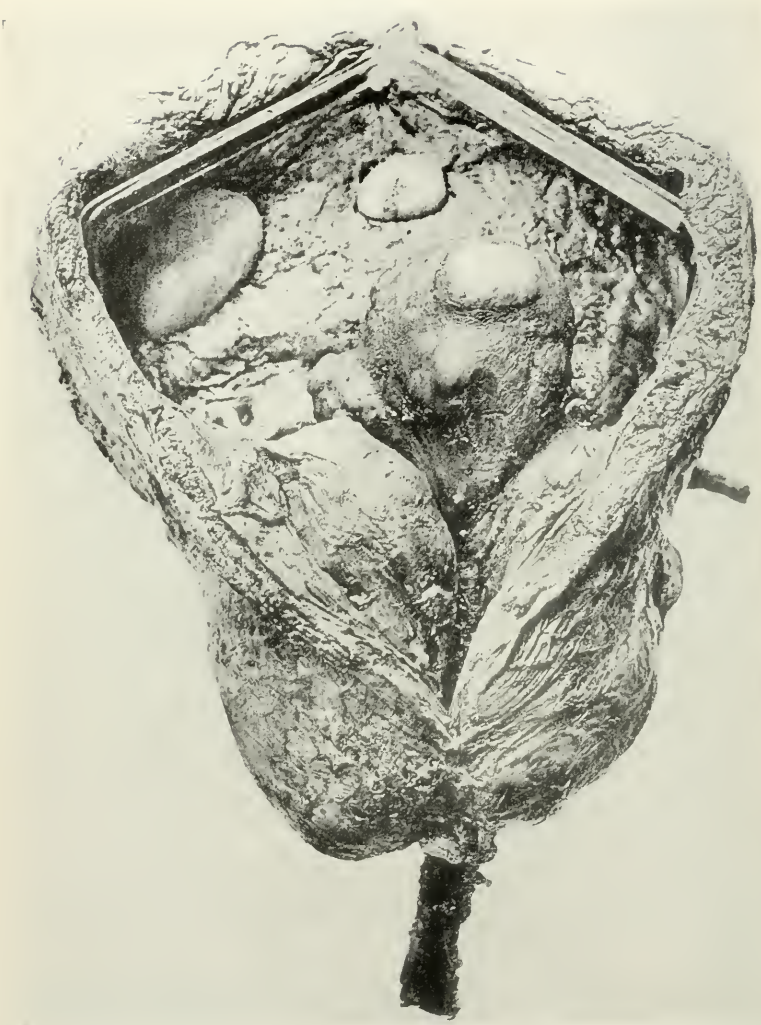

Photograph of bladder and prostate which speaks for itself. It is impossible to conceive how anyone would deny that this photograph represents a case of hypertrophy of both lateral lobes of the prostate and the median lobe. The photograph showing the distinct relation between the bladder wall and the specimen bears witness to the incorrectness of the conclusions of Tandler and Zuckerkandl when they say that such hypertrophy does not exist. (Reproduced from Francis S. Watson's work on The Operative Treatment of the Hypertrophied Prostate.)

FIG. 16.

Photograph of another specimen of obstructive hypertrophy of the prostate demonstrating another phase of hypertrophy of the lateral lobes. Position of the colliculus. In this case the two lateral lobes have developed unequally, that on the right side of the specimen being much the larger and distorting the urethra very greatly. Both lateral lobes are hypertrophied and the median lobe is represented by a thickened area which becomes a bar because of its being raised up and forced bladderward by the enlarged lateral lobes. If these hypertrophied masses originated from the median lobe, the floor of the urethra would be raised up, whereas the specimen shows the floor of the urethra only distorted in a lateral direction, while the floor is actually depressed. The position of the colliculus in this case is also well seen. (Reproduced from Francis S. Watson's work on The Operative Treatment of the Hypertrophied Prostate.)

FIG. 17.

Photograph of a perfect example of a median lobe enlargement without hypertrophy of the lateral lobes. (Reproduced from Francis S. Watson's work on The Operative Treatment of the Hypertrophied Prostate.)

In this case the lateral lobes are distinct, but not hypertrophied. The specimen shown in Fig. 18 shows well the part taken by the lateral lobes in some cases of obstructive prostatic overgrowth. The specimen was removed by the transvesical route, and the entire deformed portion of the prostate was removed in one piece. Fig. 18 shows the under surface of this prostatic mass. A rubber tube passing through the specimen indicates the position of the urethra. At the top of the specimen is seen a small collar which is the mucous membrane stripped up from the internal sphincter. This sphincter could be appreciated by a finger in the bladder. Fig. 19 is another photograph of this same specimen viewed from the anterior surface, showing, roughly, the course of the urethra, as exaggerated by the furrows produced by the presence of the rubber tube in the hardened specimen. The two lateral lobes which appear like the wings of a butterfly are joined together across the median line by a practically normal median lobe which is in no way hypertrophied. The collar of mucous membrane also appears at the top of this specimen and shows the lack of any bulging in the bladder. As far as could be appreciated by the finger, the entire prostate was removed in this case with the possible exception of the posterior lobe of the gland which was distal to the ducts, but the remains of which could not be appreciated by the finger. Examination of the cavity from which this prostate was removed, made immediately after the operation, demonstrated no tissue remaining which in any way resembled prostatic tissue. Fig. 20 is a photograph of a specimen removed the same day as the previous specimen and shows the prostatic mass as removed in one piece. The small drainage tube occupies the position of the urethra and shows it distorted and the presence of the greatly enlarged median lobe which extends into the bladder and lifts the urethra up. The bladder in this case is to the right of the specimen. As one views the specimen grossly, it would look as if the entire adenoma were one piece. When, however, the anterior commissure is divided, the specimen falls apart and forms three distinct portions; the two lateral masses, which are the lateral lobes, are greatly hyper-

trophied and compress the urethra, the course of which is indicated by the furrow (Fig. 21). To the left in the upper quadrant of the picture is seen the median lobe which extends well down into the urethra, well past the first portion of the lateral lobes, in fact, forming a wedge-shaped lobe between the portions of the lateral lobes which extend into the bladder. However, the specimen clearly shows the relations of the two lateral lobes to the urethra. Fig. 22 shows another view of this same gland which indicates more clearly the exact position of the urethra and its relations to the lateral lobes and to the median lobe. In this specimen one lateral lobe has been removed and the furrow, as indicated in the specimen, shows the relation of the urethra to both the lateral and median lobes. The lateral lobe forms the side wall for over two inches, while the median lobe, passing beneath the urethra, extends along it for an inch and a quarter.

Our own deductions are based primarily on an analytical study of our own cases, taking into account, first, the conformation of the prostatic mass as presented to the cystoscopist and judged by the eye, and the mass as found *in situ* at the time of operation and appreciated by the finger; second, a careful determination of the adenomatous mass in relation to the opening of the urethra and the sphincter vesicæ; and third, a thorough gross and sectional examination of all our specimens after removal by the transvesical route.

Professor Tandler has not demonstrated conclusively that the lateral lobes of the prostate are compressed and atrophied by enlargement of the anatomical median lobe. If he could show us the various stages of the development of this phenomenon by microscopical section, we would be convinced of his argument, but he has not presented any microscopical sections showing the transition from the adenoma involving the median lobe and atrophy of the lateral lobes. Furthermore, before we could accept his theory of the enlargement being confined only to the median lobe, it would be necessary to show that the ducts leading from this lobe were entirely distinct from the ducts leading from the lateral lobes.

FIG. 18.

Specimen removed by transvesical operation, showing under surface in a case of enlargement of both lateral lobes.

FIG. 19.

Same specimen as Fig. 18. The anterior commissure divided, showing two lateral hypertrophied lobes and the normal sized median lobe joining the two enlarged lobes.

FIG. 20.

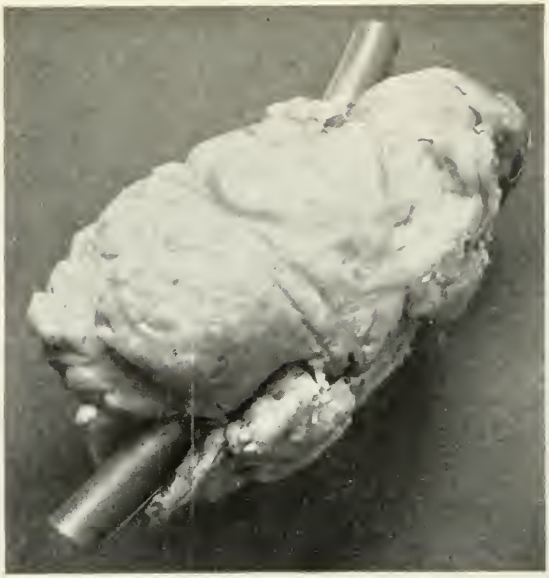

Specimen removed by transvesical operation showing the entire prostate removed in one piece.

FIG. 21.

Same specimen as Fig. 20. The anterior commissure divided allowing the hypertrophied right lobe to drop down, showing the relation of the enlarged middle lobe and the left lateral lobe to the urethra. The middle lobe is seen to form the floor of the urethra for a distance of about one and one-half inches, but does not extend as far up on the urethra as the lateral lobe.

FIG. 22.

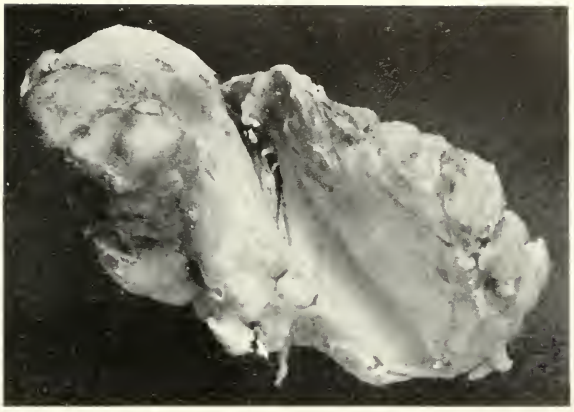

Same specimen. Shows this same condition more clearly.

FIG. 23.

A close view, through cystoscope, of a dilated ureter opening with lax walls.

II. THE CHOICE OF TREATMENT.

Assuming the diagnosis to be correct, that is, that obstructive prostatic disease exists, how shall we determine the course of treatment? And when the indication for prostatectomy is present, what is the safest procedure?

1. PALLIATIVE MEASURES.—The establishment of a catheter life, destroying an obstructing mass by using the cautery or punch, or the high frequency spark, are all but temporary expedients. Any and all of these methods may be used to insure the patient's temporary relief, but invariably the patient continues to become more enfeebled, is constantly the slave of his bladder, his mind is never at rest and finally, as a rule, he must face either an operation or death. Certainly this fact has been most forcibly demonstrated in the recent survey of our non-operated cases. These cases naturally fall into three classes, those in which the urinary obstruction is due to benign hypertrophy of the prostate, in other words, a chronic interstitial prostatitis; second, those cases in which the obstruction is due to carcinoma of the prostate; and third, tubercular hypertrophy of the prostate.

In the first class, in those cases in whom the obstruction has developed to that stage where the use of a catheter, either at intervals or every day, has become necessary to insure their comfort, infection sooner or later takes place, followed by sepsis, uræmia, etc., and the average length of life is less than three years. This is a little longer than the average time found in Squier's recently tabulated cases. All of this time, however, the patient lives in filth and misery and is a burden to himself and a trial to his friends.

In the second class of cases, the unoperated malignant growths of the prostate, no average can be stated which is of much value. The progress of cancer in the prostate is slow as a rule, but where there is much obstruction due to the growth, the combination of uræmia and the effects of the cancer often terminate the life of the patient within a year.

In the last 28 cases of benign hypertrophy of the prostate, which comprises all cases operated upon within the last two

years, during which the new method hereinafter to be described has been followed, we have secured 100 per cent. recovery. In the malignant growths covering the same period, consisting of six cases, there has been one death. In this case besides removing the prostate, the base of the bladder and the seminal vesicles were also resected.

RESULTS.—*In the non-malignant cases* above mentioned the average length of life is limited by old age and the various ills incident to its progress. All of the cases have had full control of their urine and they have returned to their normal health again. *Of the malignant cases,* one patient is living two years and two months since his operation and is now showing marked cachexia, but is still able to void his urine without the use of the catheter. A second patient is living, one year and two months since his operation, with marked symptoms of carcinoma involving the rectum, but is still able to empty his bladder. A third case died 12 hours after the operation. A fourth is still living, four months after operation, with no symptoms as yet referable to the bladder; complete control and voids normally. The fifth case was operated upon two months ago; still no symptoms of return and voids normally. The sixth case is still in hospital making a good recovery. *One case of tuberculosis* of the prostate was operated upon in which the prostate was removed by this method. The patient recovered and is to-day perfectly well, one year and four months since the operation.

2. OPERATIVE CONSIDERATIONS.—*The chief indication.* If practitioners and surgeons will hold in mind the fact that *the chief indication is primarily to relieve the retention of urine rather than the removal of the prostate,* the entire subject of obstructive prostatic disease will assume a different aspect. If we could dissuade surgeons, as a rule, from the course of immediately taking out a prostate which is known to be obstructive, we would do much to help the cause of the prostatics.

There are two methods of accomplishing the relief of the retention of urine, and one of these two methods should comprise the first step in every operative encroachment upon the

bladder for this disease. First is the use of an indwelling catheter which systematically drains the bladder for a definite period of time until the kidney has reacted from the changed condition. This method may also be used to clear up the cystitis. The second method is a suprapubic cystostomy and the introduction of a permanent catheter occupying the cystostomy wound for the same purpose as an indwelling catheter.

Before discussing the relative values of these two methods, one of which should always be employed before prostatectomy is considered, I wish to present a few facts which demonstrate that retention of urine in the bladder in prostatic disease has a very distinct and fundamental effect upon the general economy.

The Kidney as Affected by Prostatic Hypertrophy.—First, clinical evidence: The clinician will observe, in cases of prostatic disease in which there is considerable retention of urine, that the most marked symptoms will be evidences of intestinal stasis, loss of appetite, loss of sleep, changes in temperament, mental degeneration, lack of personal pride, loss of weight and a general deterioration of the entire organism. Aside from this, further examination will show various phases of uræmic poisoning; in many cases a very marked increase in the secretion of urine with low specific gravity. Frequently the amount of urine will reach 150 ounces in 24 hours and its specific gravity be as low as 1002. In a recent case the 24-hour record was over 300 ounces. This, of course, is an index of functional derangement of the kidney. The rapid disappearance of all these clinical evidences of disturbed renal function, which follows draining of the bladder, shows the direct relation of cause and effect.

We have both acute and chronic, partial and complete forms of obstruction.

In the cases of *chronic partial obstruction* it has been noted in general that the amount of urine secreted is increased, providing the bladder is strong enough to regularly overcome the partial obstruction, and partially empty the bladder so that at no time the back pressure from the bladder is continually great. Where the musculature of the bladder is not so strong,

and there is a chronic retention of a considerable amount of urine with very little overflow, the amount of urine secreted will often average as high as 120 to 150 ounces in twenty-four hours with a low specific gravity.

Where we have a contracted bladder with greatly thickened walls, in which there is only a small amount of retention, and the amount of retained urine almost entirely fills the contracted bladder, the urine is passed very frequently and in small amounts. Such a bladder may contain only two or three ounces and is almost continuously full. Under such conditions the kidney seems to diminish its secretions. The total amount secreted in twenty-four hours may be very little, finally resulting in complete anuria.

The other cases are those of acute retention of urine, in which the kidneys act freely until the bladder is filled to its capacity, at which time the kidneys stop acting entirely. It must be remembered that the bladder will never rupture from overdistention due to accumulation of urine.

Aside from the clinical evidence of renal infection and renal insufficiency already presented, the most striking evidence of renal injury due to prostatic obstruction is presented in those cases dying from the disease. Autopsy shows a variety of conditions existing in the kidney, the lesion most common to all being a hydro-ureter beginning immediately above the bladder, resulting in various degrees of hydronephrosis and destruction of the kidney parenchyma. This in turn is influenced by the degree and duration of the obstruction and in more advanced cases is accompanied by infection, the formation of renal calculi, and, in some cases, by actual infection and destruction of the kidney parenchyma.[2]

To the mind of the writer those lesions are brought about by two mechanical conditions: 1. The hypertrophy of the muscular walls of the bladder through which the lower end of the ureter passes and, 2, the constant presence of residual urine which helps to keep the muscles compressed and forming a

[2] Wade: Prostatism, Fig. 40. March ANNALS OF SURGERY, p. 334.

chronic obstruction extending over that portion of the ureter which passes through the bladder wall. It is the exceptional case in which the infection is an ascending one, but usually, in my opinion, it is due to hematogenous and lymphatic infection of a tissue whose resistance has been greatly lowered by mechanical obstruction.

Second, objective symptoms: The cystoscope shows that many changes have taken place in the bladder. First, we note that the muscular walls are markedly changed. They are hypertrophied and trabeculated, and false and true diverticula are formed, and occasionally calculi of various sizes and shapes are seen. Occasionally, also, the infection of the renal pelvis which follows retention of urine predisposes to the formation of renal stones which may be shown on the X-ray plate.

The cystoscope, as a rule, shows the *ureter opening* raised up on a ridge with the interureteric fold quite distinct. The ureter opening in the majority of cases is normal with the exception that it is changed by the general muscular hypertrophy which surrounds it. Occasionally the ureter opening is dilated, as is seen in the accompanying illustration (Fig. 23).

Third, the operative proof: From a careful study of a series of cases in which a preliminary cystostomy was done, certain phenomena were repeatedly observed which seemed to justify us in dividing the sequelæ to advanced prostatism into three phases. It has further emphasized in our minds the peculiar balance existing between the heart, kidney, secretion of urine, and the nervous control of these in the patient who has gradually become used to over-distention of the bladder. The pathology of this condition has already been referred to.

We have learned not to rely upon any one clinical sign or symptom in judging the fitness of the patient for operation. We have learned that the balance between the various elements of the system are so adjusted that a disturbance of one element will bring to light weakness in some of the other elements which has not been suspected, for example, *the phthalein test.* This *may be very deceptive.* The patient may show 60 to 70 per cent. of excretion of phthalein in two hours before anything

has been done to relieve the retention of urine. But disturb the retained urine in the bladder and all of the other elements of the system are thrown into confusion. The back pressure is relieved; decompression of the kidney follows; swelling and congestion of the kidney takes place; and the functional capacity of the kidney immediately drops to a very low point. The outward signs of the derangement of this unbalanced kidney are very evident. This is the second phase. It is our belief that many of the cases which have died following operation are the result of a lack of appreciation of this second phase of a renal disturbance in prostatics. Many deaths have been reported on the third to the fifth day following a one-step prostatectomy, when the patient was seemingly doing well; but when we add the phenomena of the second phase to the shock of the major operation with its loss of blood and the depressing effect of the general anæsthetic, it can be easily appreciated why these deaths take place, and many will agree that the overtaxed heart and the system overloaded with toxins which the kidneys should separate from the blood are the cause of death. Our extended observations have shown us that nearly every prostatic will present these three phases, and this fact has influenced us very greatly in favor of the two-stage operation in every case of benign hypertrophy.

III. THE THREE PHASES.

The results of our observations are graphically shown on the accompanying chart, Fig. 24, which shows the average condition which prevails in many advanced cases of obstructive hypertrophy of the prostate.

The First Phase.—For the first day, the day on which the suprapubic cystostomy is done, the blood-pressure frequently registers from 200 to 220 mm. of mercury; the urinary output for 24 hours will average from 70 to 120 ounces; the phenol-sulphone-phthalein test will frequently average above 60 per cent. in two hours and the urine will show only a trace of albumin. If these conditions are considered by themselves, they will give us a false impression of the actual condition of the

FIG. 24.

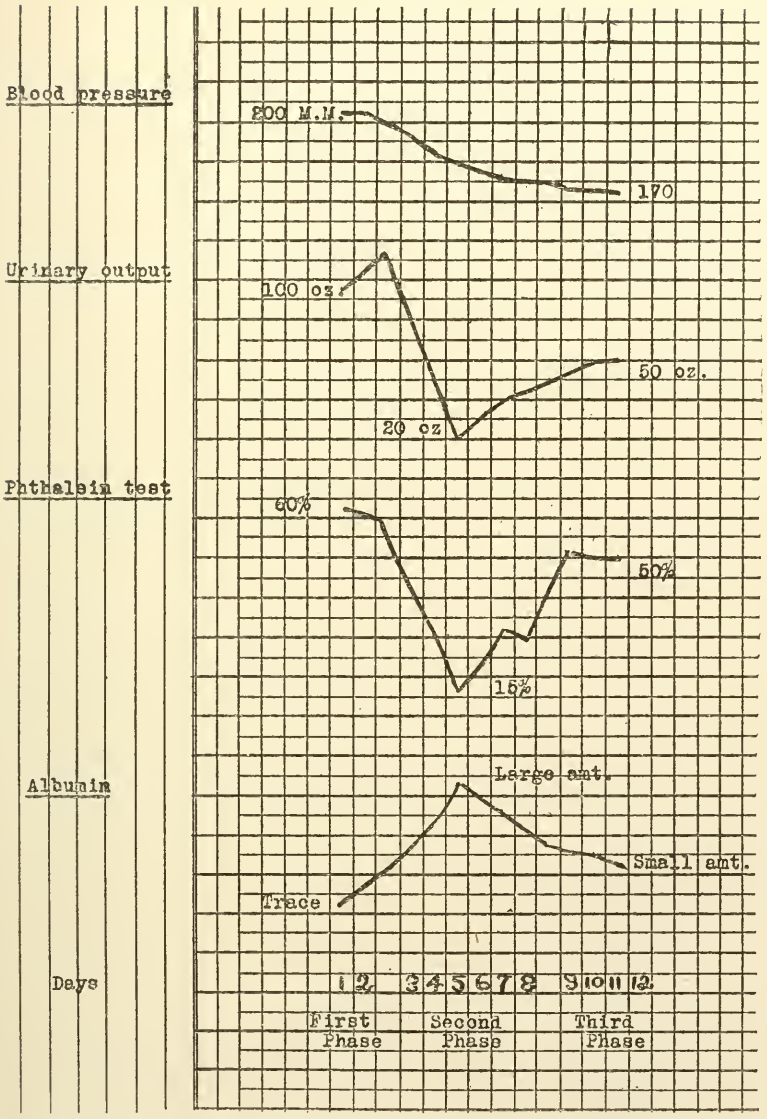

Chart showing the three phases following suprapubic cystostomy in an advanced case of obstruction due to prostatic hypertrophy.

First phase: Includes the first and second day, the suprapubic cystostomy being done on the first day. If one would observe this chart excluding the following days, the conditions would seem to be favorable for any operative encroachment. See page 514. If taken alone, this surely would seem to indicate a safe surgical risk.

Second phase: This phase extends over the third, fourth, fifth and sixth days after a suprapubic cystostomy. It shows a very marked decrease in urinary output during that time,

(Legend continued on next page.)

patient. For example, if the patient's blood-pressure registered 200, was passing 90 ounces of urine in 24 hours with low specific gravity and with only a trace of albumin, we would be rather suspicious of the functional capacity of the kidneys. But when we make a phenol-sulphone-phthalein test, and find that the output in two hours is 60 per cent. or more, it rather leads us to believe that the actual functional capacity of the kidney is greater than the specific gravity of the given specimen would lead us to believe.

The Second Phase.—A second glance at the chart will show a very different condition existing on the third or fourth day after the bladder has been opened and drained. Here we see a lowered blood-pressure, probably between 170 and 180. The urinary output has suddenly dropped to from 15 to 20 ounces in 24 hours; the amount of albumin in the urine has increased enormously and often the urine itself boils almost solid. On the third to fourth day, the phenolphthalein test shows the actual functional capacity of the kidney at this most critical time to be only *15 per cent.* This, then, is the change which has taken place simply following a suprapubic drainage of the bladder without any loss of blood or other surgical shock due to anæsthesia or prolonged manipulation. Add to this, then. the shock of a prostatectomy with its general anæsthesia, a very considerable loss of blood and the shock consequent to pain, and one does not wonder that so many cases have died on the third, fourth and fifth day from no apparent cause which could be demonstrated.

The Third Phase.—Passing on then to the third phase of

a large increase in the amount of albumin present, but most important of all the drop in functional capacity of the kidney from 60 to 15 per cent.

Third phase: Showing the reaction and the recovery of the kidney after ten days. Blood-pressure 170, urinary output averaging 50, phthalein test 50 per cent., and a smaller amount of albumin present in the urine. Comparing this phase with the first phase we find a lower blood-pressure, a normal urinary secretion with an increased specific gravity, a lowered functional capacity of the kidney, as attested by the phenolphthalein test and a larger amount of albumin present in the urine than during the first phase. When, however, the reaction from this phase following enucleation of the prostate is considered, what a much better combination of circumstances exist in this phase than in the first phase. Following prostatectomy, the blood-pressure falls still lower, due to the loss of blood. The urinary output decreases most markedly during the first 24 hours, but recovers rapidly until, on the third day, it is practically normal. The phthalein test shows lessened reaction, but it never drops as low as was found in the second phase after suprapubic cystostomy, so that 50 per cent. according to the phthalein test in the third phase shows a very much greater relative functional capacity than 60 per cent. in the first phase. This we consider a point of very great importance. The amount of albumin following the operation is an unknown quantity.

the condition following drainage of the bladder, we find in the average case that on the seventh to tenth day the blood-pressure has decreased to from 160 to 170 mm., the urinary output has increased to from 40 to 50 ounces in 24 hours, the phenolphthalein test shows a reaction of the kidney from an output of 15 per cent. to an output of 50 per cent., and the amount of albumin contained in the urine has decreased very markedly, but still shows a small amount present, more than was present before the cystostomy and very much less in amount than was found on the third or fourth day.

Now if the prostatectomy is performed, the effect upon all these phenomena is quite different than was found after the preliminary cystostomy. The blood-pressure falls still lower, the urinary output decreases very little; the functional capacity of the kidney does not fall more than ten points; it is difficult to ascertain the amount of albumin present in the urine on account of the presence of the wound in the bladder, but at no time is it as great as was found on the third or fourth day after the cystostomy was performed.

By following this method we entirely avoid the second phase after the prostatectomy.

This conclusion is based upon the study of our last 28 successive cases, all of which have been operated upon after this method and all of which have recovered. It must be remembered that the second phase will last from a day or two to many weeks, and *if the reaction to the third phase does not take place within ten days to two weeks, the surgeon should not under any circumstances be persuaded to remove the prostate,* because if he does the chances are very much in favor of a fatal outcome. In one of our cases a gastric uræmia developed on the third or fourth day and *it was impossible to remove the prostate for over five weeks.* At the end of that time the third phase of the phenomenon appeared and the prostate was removed without any shock to the patient, followed by uncomplicated recovery.

All clinical observers naturally realize that the different stages vary in many cases as to their extent and their duration.

This point may best be emphasized by the following illustrative cases:

Case I.—*Diagnosis: Hypertrophied prostate; complete obstruction; vesical calculus; mitral insufficiency; chronic interstitial nephritis; double inguinal hernia.*

Condition on entrance to hospital July 14, 1913: A large framed man, *eighty-two years of age*, who has led an active seafaring life. For ten years has had increasing frequency of urination and for two years has used catheter daily for the removal of residual urine; *now depends entirely upon a catheter which he uses every four hours.* The use of the catheter is becoming increasingly difficult and painful and has already provoked several attacks of double epididymitis. There is present a moderate cystitis. There are evidences of a generalized *arteriosclerosis* with some *mitral insufficiency* and a moderate degree of *chronic interstitial nephritis.* He has also a *double inguinal hernia.* Notwithstanding these many physical defects, he still presents evidences of considerable vital force and, in the opinion of the surgeons, is a reasonably fair operative risk in the face of the marked urinary crises which are developing. Blood-pressure, 220 mm.; urinary output, 80 oz.; phthalein test, 57 per cent.; albumin, a trace.

First Operation.—On July 15, 1913, a preliminary suprapubic cystostomy was done by Dr. L. S. Pilcher under local cocaine anæsthesia, using 1 per cent. solution of cocaine.

The bladder was exposed in the usual manner without complaint from the patient. Upon opening the bladder a medium-sized *uric acid calculus* the size of a lima bean was detected and removed. A polypoid development of the middle lobe of the prostate perceived. A Pezzer catheter was secured in the bladder and the wound sutured. Patient sustained no shock from the operation. During the following week he remained very comfortable. Urinary output dropped to 30 oz.; phthalein test to 18 per cent., etc. (see Fig. 25). There was a gradual lessening in the blood-pressure and a notable improvement in his general well-being. A phenolphthalein test showed a steady increase in the renal activity.

Consulting the accompanying chart, Fig. 25, it will be seen that the blood-pressure had been reduced to 170 and the functional activity of the kidneys had reacted from the first period of depression. The patient's condition was very satisfactory, despite his

FIG. 25.

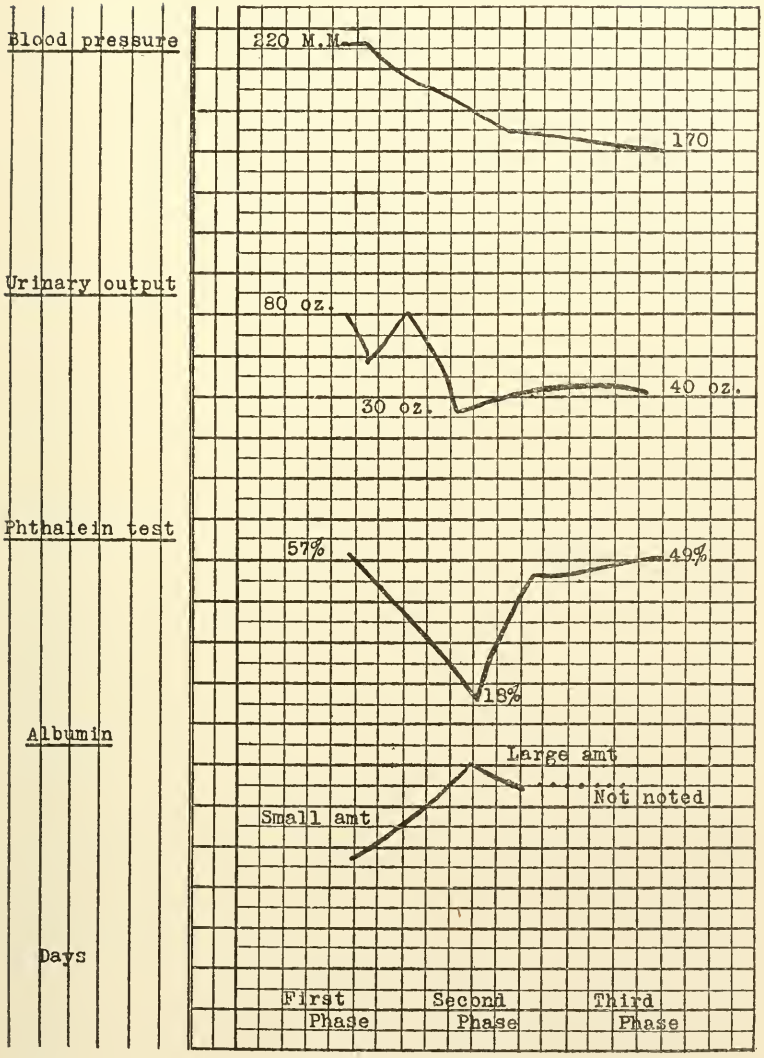

THE THREE PHASE CYCLE.

Chart of Case I. Showing the three phases in a patient 82 years of age. Note the marked difference between the three phases—especially the drop from 57 per cent. to 18 per cent. in the renal efficiency and the large increase in amount of albumin. Prostate enucleated during third phase. Recovery.

age of 82 years and his mitral insufficiency and chronic interstitial nephritis. It was, therefore, deemed proper to attempt enucleation of his prostate.

Second Operation.—Transvesical prostatectomy. Under ether anæsthesia, the finger was passed through the suprapubic opening and without removing any of the sutures the prostate was enucleated in three minutes. Some packing of the prostatic pouch was necessary to control a moderate hemorrhage. There was no shock following the operation. Draining tube and packing removed in 24 hours and a Pezzer catheter introduced. The Pezzer catheter removed on the fourth day followed by uninterrupted healing of the wound and full restoration of function. Six months after the operation the patient is quite well and is urinating normally.

It seems quite evident to us that it was safer ten days after the primary operation to remove the prostate than it would have been at the time of the primary operation. With the blood-pressure of 170 instead of 220, with the kidneys relieved of the disorganization incident to retention of urine, and with a well-balanced functional activity, the prostatectomy could be undertaken without danger to the patient. In our series of cases the depression which occurs from the third to the sixth day has been so constant that it is a real factor to be reckoned with in all these cases, and it is our belief that no prostate should be removed until this period of reaction has been passed.

In some cases the second stage lasts two, three, four or more weeks. During this period after the suprapubic cystostomy all of the clinical features of the case preclude the possibility of a prostatectomy and not until a fully developed third stage appears should the prostate be removed. The following case in which the patient developed a gastric uræmia, and massive œdema of the legs, will serve as an example.

Case II.—*Diagnosis: Obstructive hypertrophy of prostate; gastric uræmia.* The patient was admitted May 9, 1913. General health good. Considerable obstruction. No symptoms of kidney trouble excepting a slight amount of albumin which was present.

First Operation.—Suprapubic cystostomy; Pezzer catheter. May 10, 1913, operation quickly accomplished under local anæsthesia. The day following operation passed 24 ounces of urine, clear, large amount of albumin present; 26 hours after operation

began to vomit; 8 hours after operation hiccoughs began and continued intermittently for 24 hours. Second 24 hours urinary output dropped to 27 ounces, still clear; vomiting continued; urine almost solid with albumin. Third 24 hours some nausea, no vomiting. Fourth 24 hours vomiting recommenced. Hiccoughs lasted for 14 hours, quite restless. Urine became bloody, almost solid with albumin—29 ounces in 24 hours. Fourth day very sleepy, hiccoughs continuing, legs showed slight swelling, urine bloody. Fifth day slight hiccough, urine clearer, sat up. Patient showed a gradual improvement with the exception of the swelling in his legs, which increased so that both legs soon became very badly swollen.

Coincident with this no phenolphthalein test was made on account of the large amount of blood and albumin present. June 2, phenolphthalein test showed 30 per cent. excretion the first two hours; June 9, one week later, showed 22 per cent. excretion first two hours; June 15 showed 21 per cent.; July 1, phenolphthalein test showed the excretion to be 48 per cent. in two hours. The patient's general condition showed a coincident improvement, swelling of the legs entirely disappeared, the amount of albumin in the urine very greatly decreased so a further operation was deemed advisable.

Second Operation.—Transvesical prostatectomy. July 5, 1913. Suprapubic catheter removed and with the finger passed into the bladder through the suprapubic opening the prostate was easily removed. There was considerable hemorrhage which necessitated the introduction of packing. Reaction from the operation was very slight. Twenty-four hours after operation was sitting up in bed; 48 hours after operation the drainage tube was removed from the wound and Pezzer catheter re-inserted; 59 ounces were collected through this catheter during the 24 hours, with hardly any leakage. On the fifth, sixth and seventh days he evidenced some stomach irritability and vomited a little, but the attack passed off quickly. On the ninth day began to urinate a little. Wound healed promptly and the patient was discharged cured August 2.

It is not only the kidney and its function which must be considered, but it may be that it is the heart that is the weak link in the chain, and in order to ensure a safe operation the

FIG. 26.

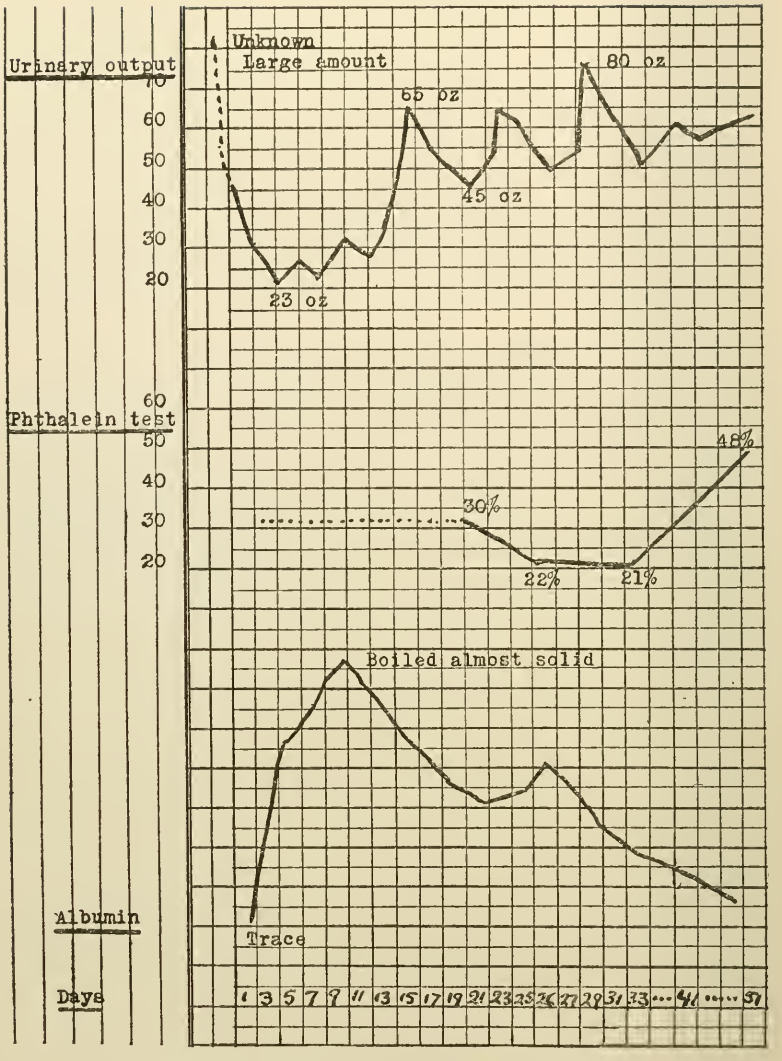

THE THREE PHASE CYCLE. PROLONGED SECOND STAGE.

First phase: Aside from the large amount of urine passed, the patient's condition was almost ideal.

Second phase: Which followed the suprapubic cystostomy was unusually severe. Marked diminution in the amount of urine. Urine boiled almost solid. Gastric uræmia supervened. Enormous swelling of the legs. Patient in desperate condition. At the end of 51 days, however, all of the uræmia symptoms had disappeared. Amount of urine passed was normal.

Third phase: At end of 50 days phthalein test showed 48 per cent. Urine showed very small amount of albumin. Patient's general condition satisfactory. Prostate enucleated with hardly any post-operative reaction. Patient made perfect recovery.

kidney must be in the best possible condition before the enucleation is undertaken, for if, with a failing, dilating heart the renal function fails, there is little hope for the patient's recovery. The following case illustrates this point:

Case III.—(Lynch.) Patient was a man whose actual age was sixty-five years although his appearance was that of a man of about eighty. For two years he had been struggling against the ravages of prostatic disease and had gradually become emaciated. Was rapidly losing his strength and had already lost his appetite. He had been catheterized frequently, but this had ceased to give relief and at the time of his examination was passing his water every 15 to 20 minutes day and night. As the result of a metal instrument being passed into the urethra he developed an acute retention with bleeding into the bladder. When seen by me he was in greatest distress and the bladder dilated up to the umbilicus. His pulse was small and weak. He was in considerable shock.

First Operation.—Suprapubic cystostomy. He was hastened to the hospital and immediately the bladder was opened under local anæsthesia, and a large amount of blood clot and urine were brought away and a Pezzer catheter sutured into the bladder and the wound closed around it.

The patient reacted very well from the operation. The following day his temperature reached 102°, his pulse 100, urinary output averaged 25 ounces. Renal sufficiency as shown on accompanying chart, which was 69 per cent. of phenolphthalein excreted during the first two hours immediately after the operation, dropped on the third day to 20 per cent. in two hours under the same conditions. His pulse was weak and soft but not very rapid. His general condition was good. One week later the phenolphthalein test showed an elimination of 48 per cent. in two hours (Fig. 27). Two days after this, when examined, his condition was considered proper for operation, and under ether anæsthesia this was accomplished.

Second Operation.—Enucleation of prostate. Time of enucleation 1½ minutes. Control of hemorrhage, which was considerable, by packing as above described. The day following the operation patient's condition good. Packing and drainage tube removed. Pezzer catheter inserted. Urinary conditions good. On

third and fourth days very considerable cardiac insufficiency, pulse extremely weak, intermittent and general weakness (see chart, Fig. 28); temperature 101.8°, pulse 130, respirations 40. Under

FIG. 27.

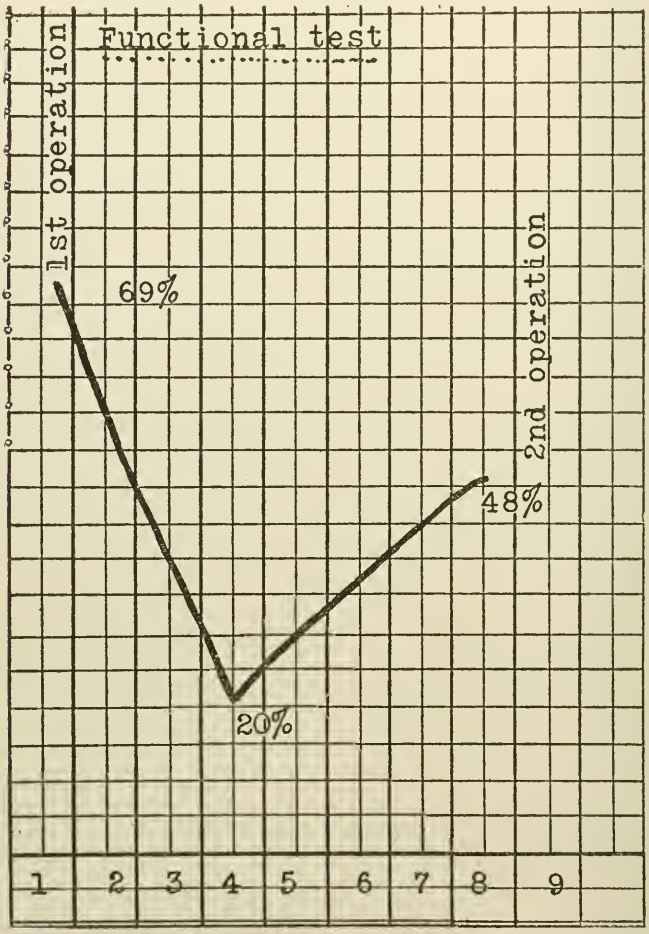

Chart showing drop in renal function during second phase from 69 per cent. to 20 per cent. (Case III.)

proper medication the conditions gradually returned to normal, which they reached on the fourth day. However, this chart will show the dangerous reaction following the operation which, if it had occurred coincident with the shock of the primary operation

FIG. 28.

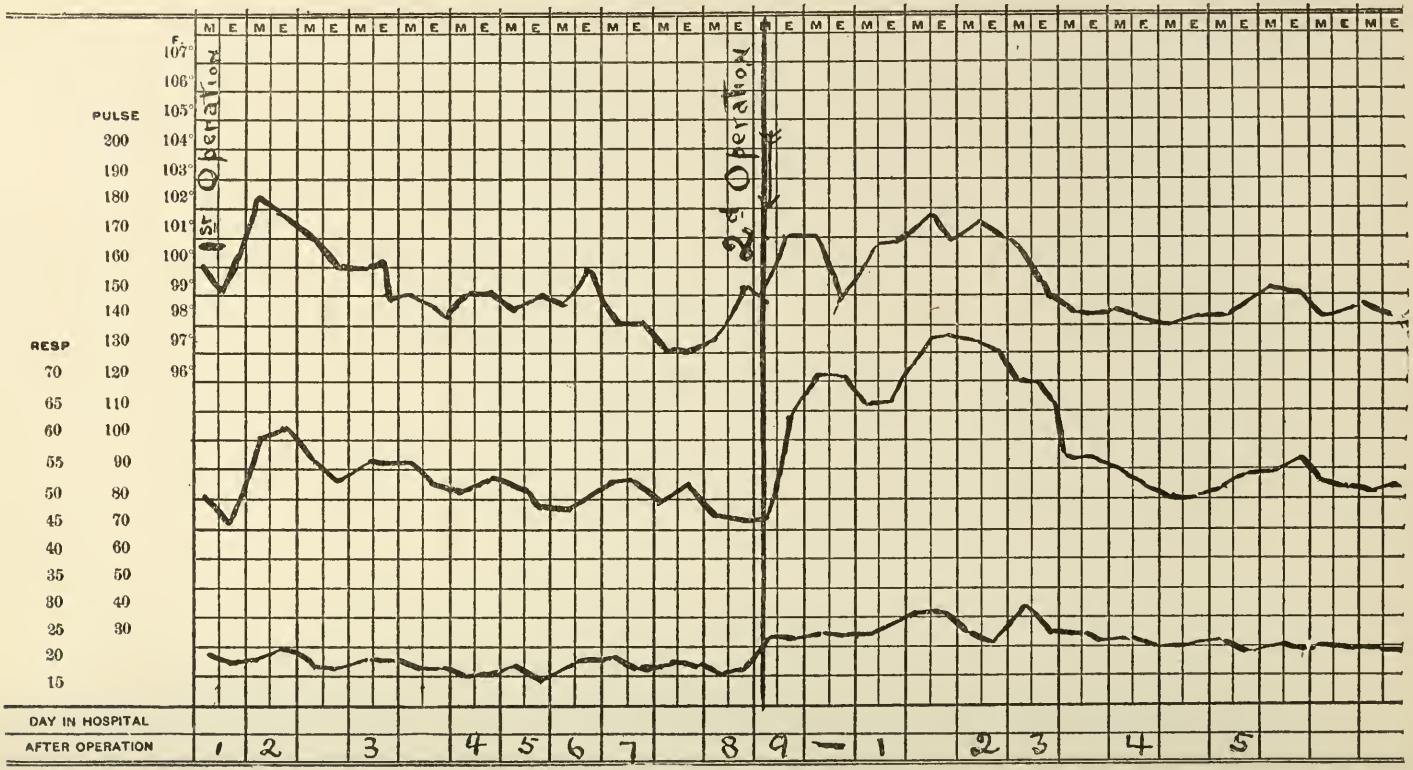

Chart showing pulse, temperature, and respiratory conditions in Case III.

with a very marked decrease in the renal sufficiency, the patient would probably have died on the second or third day. As it is the patient recovered entirely; he passed his urine by the urethra on the ninth day, and the wound was closed completely on the twenty-second day. His present condition is satisfactory.

As already referred to, in cases of enormous dilatation of the bladder with œdema of the legs, scrotum, etc., the three-phase cycle shows a remarkable curve when traced on the chart. The accompanying diagram, Fig. 29, shows the condition existing in a patient still under our care. During the first 24 hours the patient passed 249 ounces of urine, a catheter being used to withdraw the amount in small quantities and never emptying the bladder, that viscus being continuously dilated as high as the umbilicus. On the second day more urine was withdrawn at a time and the urinary output was 308 ounces, specific gravity 1002. Following the chart it will be seen that gradually the urinary amount decreased and that on the fourth day the bladder was completely emptied for the first time by catheter, the amount passed during the 24 hours being about 120 ounces. This modified second phase shows a preliminary rise and the enormous output of urine would unquestionably have overwhelmed the patient had a prostatectomy been done, or even a suprapubic cystostomy.

Fig. 30 is the pulse chart of the same patient and shows the remarkable effect the condition had upon the action of the heart. On the twelfth day the phthalein test showed a 40 per cent. output, but the pulse was extremely unreliable. Five days after the suprapubic cystostomy the phthalein test showed an output of 67 per cent. and the pulse at that time would not permit a prostatectomy. In fact, with a heart so badly damaged and a kidney which had been exposed to so much pressure, the date of the prostatectomy must be put off for some weeks.[3] Other cases show only a mild degree of depression in the second phase and it would undoubtedly have been perfectly safe to remove the prostate at the first operation, but as yet I have not

[3] Thirty-eight days after the cystostomy the prostate was removed and the patient has made a good recovery.

FIG. 29.

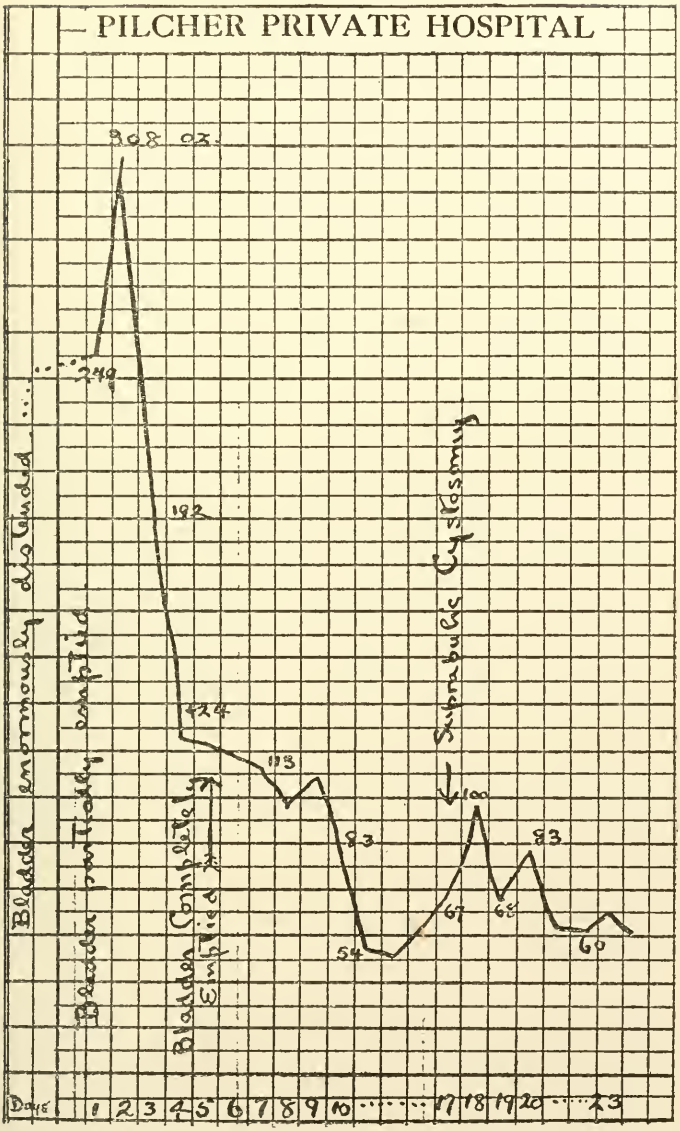

Chart showing remarkable first phase of chronic prostatism. Bladder distended above umbilicus. Patient in collapse. Partial decompression of kidney developed urinary output of 308 ounces of urine in 24 hours. The second phase showed a gradual drop in urinary output, with a very marked increase in the amount of albumin. Suprapubic cystostomy on twelfth day showed very slight reaction from kidney. For the first twelve days, urine was removed by catheter.

been able to tell which cases fall within this class until after the cystostomy has been performed.

How shall we decide, then, when it is safe to remove the prostate in a given case?

First, our judgment is based on the general condition of the patient. When his appetite returns and his sleep becomes normal, when his temperature, pulse and respiration are nor-

FIG. 30.

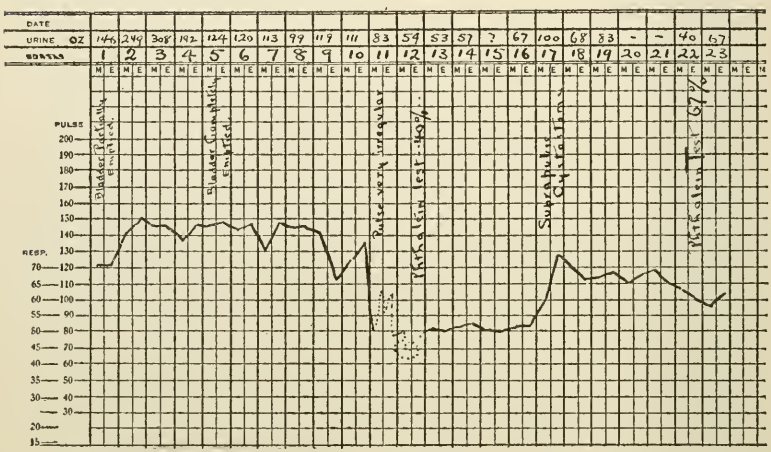

Pulse chart of same patient whose urine chart is shown in Fig. 29. Partial emptying of the bladder caused pulse to rise to 150 beats per minute. On the eleventh day heart action changed suddenly, as indicated on the chart, and its rhythm and rate were very irregular. The heart balance was gradually established and the suprapubic cystostomy did not disturb it very much.

mal, and when the renal output has returned to normal limits, we consider these a fair index of the general physical well-being of the patient.

Second, we do not advise prostatectomy until all the gross uræmic and nephritic symptoms have disappeared. A moderate amount of albumin in the urine is no contra-indication. The condition of the blood-pressure is also a valuable index.

Third, the phenolphthalein test is of value only as taken in connection with other signs. In the first place, one must consider the results of the phthalein test before the preliminary cystostomy; then the phthalein test taken on the second, third

or fourth day, and third, the functional reaction of the kidney to this test at the end of a week or ten days. It is a mistake to rely entirely upon this test, especially before the cystostomy has been done. For example, the test may show excretions of more than 50 per cent. in the first two hours before the preliminary cystostomy, but the reaction may drop on the second or third day, after relief of the retention of urine, to below 15 per cent., which is a true index of the functional capacity. When, however, the period of depression is passed and the reaction returns to 50 per cent. after the retention of urine has been relieved, this then becomes a fair index of what we can expect the kidney to do after the prostate has been removed.

Catheter Drainage of the Bladder.—There are some cases in which catheter drainage of the bladder must be used as a preliminary to the suprapubic cystostomy, such as cases where there is an enormous distention of the bladder with œdema of the legs, scrotum, and penis due to pressure. If a cystostomy is done and all of the urine is withdrawn at one time from the bladder, the shock and decompression of the kidney thus occasioned may bring on a fatal uræmia or a fatal hemorrhage. One such case was seen by the writer at the Jewish Hospital in Brooklyn where the bladder, which was enormously distended, was suddenly emptied; the patient promptly died. A second case under the care of the writer at St. John's Hospital, in which 72 ounces of urine was withdrawn from the bladder, was followed by a dangerous hemorrhage into the bladder.

1. *Indications for Catheter Drainage.*—Some operators prefer to use catheter drainage for a week preparatory to every transvesical prostatectomy. It is always indicated in cases where the residual urine amounts to 30 ounces or over.

2. *Dangers.*—Sudden withdrawal of all of the urine may cause death from shock, uræmia or hemorrhage. The presence of a catheter in the urethra may occasion infection, and in a number of reported cases death has followed its use.

3. *General Rules.*—If catheter drainage is established, the bladder should not be emptied all at once, but the urine grad-

ually withdrawn and, depending upon the amount present and the amount secreted by the kidney, the amount drawn should be regulated.

It is an interesting fact that the control of the amount of residual urine in cases of enormous distention of the bladder will regulate the output of urine through the kidney. In connection with these cases no drugs should be given to stimulate the heart or change its action until there is some very absolute indication for the same, for harm may be done, preventing the establishment of a normal balance, as the heart adjusts itself to the new conditions found in the kidney.

IV. SUPRAPUBIC CYSTOSTOMY.

First step, preparation of the patient. Skin, usual iodine preparation. Anæsthesia, novocaine 2 per cent. by preference. Incision, vertical.

Technic of Operation.—Usual incision beginning just above the pubis is made through the skin and superficial fascia. The sheath of the rectus is divided in the median line, the recti muscles are separated, exposing the prevesical fat and fascia. The muscles are held apart by a specially devised retractor, modified from the Mayo-Collins appendectomy retractor. The advantage of this retractor is that the curved blades are in a straight line at the point where they enter between the muscles, and after they are entered they present a concave surface to the muscular face which they wish to retract, which keeps them from slipping out of the wound. Then the third arm of the retractor is placed later. When the prevesical space has been exposed, the finger is entered until it reaches the superior surface of the symphysis. With this as a landmark, the finger covered with gauze is used to strip the fascia and lymphatic tissue from the anterior wall of the bladder. It is often of advantage to have the bladder partially filled with water, for then it is somewhat easier to clean off the anterior surface of the bladder with the finger. This stripping away of the tissue with the finger is carried up to the peritoneal fold. The peritoneum is not disturbed unless it

reaches far down over the anterior surface of the bladder. If this is so, the peritoneum is stripped up somewhat. With the bladder surface freely exposed, the third arm of the retractor is placed over the bit of gauze to hold up the fat covering the peritoneal fold.

Securing the Bladder.—To hold the bladder in place a silverized catgut retention suture is passed through the wall of

FIG. 31.

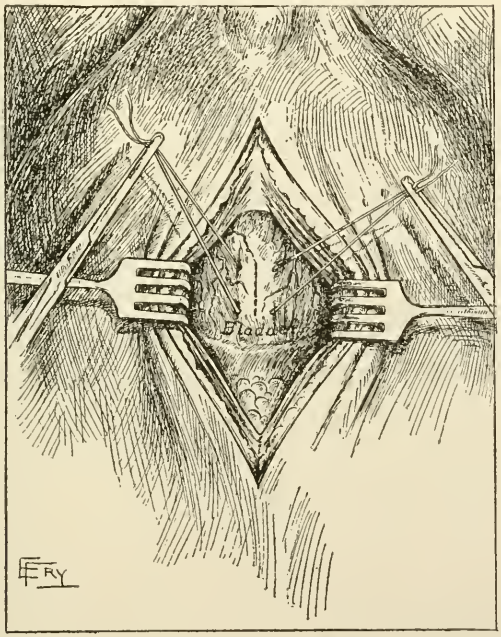

Second step in the preliminary cystostomy. The bladder wall is seen exposed and the position of the incision is indicated near the fold of the peritoneum. The two stay sutures are in place and hold the bladder wall up. As soon as these sutures have been introduced the fluid is withdrawn from the bladder.

the bladder near the point at which the bladder is to be opened (Fig. 31). The water is then withdrawn from the bladder through the catheter and the bladder washed clean. Then holding the wall of the bladder out through the abdominal wound, a knife is thrust into the bladder. The knife is withdrawn and the finger enters the bladder and examines the interior of the bladder to determine the presence of stone or

any foreign body. A foreign body, if present, is then removed. The condition of the prostate and its conformation and general character is then studied with the finger. The only point at which the patient will complain of pain is when dragging on the bladder wall or when examining the bladder with the finger through the bladder wound. Examination of the interior of the bladder can be done quickly. The finger is then withdrawn and a Pezzer catheter is inserted into the bladder wound (see Figs. 32 and 33).

The Point at Which the Bladder is to be Opened.—Incision into the bladder is made as near the peritoneal fold as possible, for healing takes place more rapidly at this point, and when a fistula is formed, the urine enters the fistula less easily at this point.

Draining the Bladder.—The Pezzer catheter, as mentioned before (Fig. 33), is fixed in the anterior wall of the bladder, then, using the same suture that was placed for the retraction suture, a purse-string is made in the bladder wall around the catheter. This suture is of catgut. It is tied, being careful to tuck in the muscular wall of the bladder around the catheter. This produces a slight spur in the interior of the bladder which, after the catheter is removed, favors early healing. This suture when tied insures a water-tight joint around the Pezzer catheter. The wound is then reconstructed. The prevesical space is carefully obliterated by the catgut suture. The fascia and muscles are sutured together with chromic gut. The skin is sutured with silk. In other words, all of the planes of tissue are brought together again in their natural position and the only opening is the line through which the catheter emerges. It is possible to do this in these cases because the joint around the Pezzer catheter is water-tight and there will be no leakage for over a week. The result is that *we have a primary union of the wound, a thoroughly drained bladder and the first step of our transvesical prostatectomy already completed.*

In any transvesical prostatectomy most of the time will be consumed in making the suprapubic incision and in closing

the same. By this method this step of the operation is already completed before the prostatectomy is attempted.

Whatever shock is going to take place from this encroachment on the urinary apparatus in cases of prostatic hypertrophy will become evident on the second to the fifth day after the suprapubic cystostomy. The *patient is in the best possible con-*

FIG. 32.

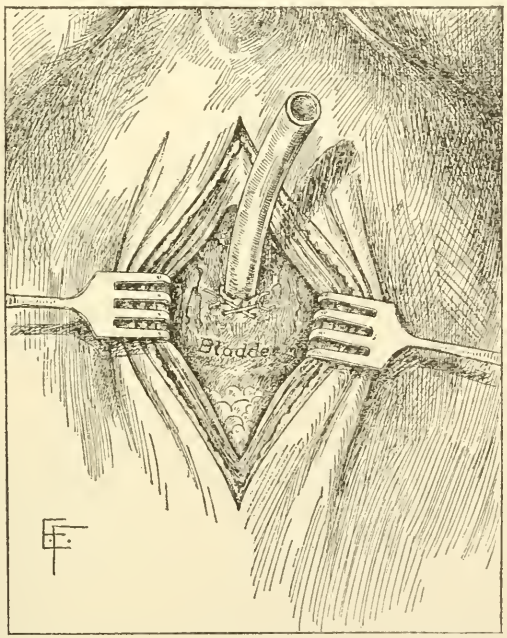

Shows the way in which the Pezzer catheter is fixed into the bladder wound,—the stay suture from one side being tied on the opposite side of the tube including some of the bladder wall, and the one from the other side tied in a similar manner. These will hold the tube firmly in place. A purse-string suture is used for the same purpose.

dition to overcome this shock because there has been no loss of blood, no general anæsthetic, and *no special pain,* all of which factors tend to decrease the resisting powers of the organism. Almost without exception in cases where there has been any great retention, there is a marked renal reaction which occurs during the first week, as previously noted. If this, then, can be eliminated as a factor of the prostatectomy itself, it seems to us that it is our duty to do this.

Two other methods have been devised as the first step of the transvesical enucleation. First, the use of a permanent catheter. This question has already been discussed (p. 528). The objections to it are: In the first place, it is most disagreeable to many patients; in the second place, it almost invariably excites a urethritis which frequently causes an infection of the epididymis, and sometimes affects the testicle. These are unfortunate complications. In the third place, fatal sepsis has more than once followed the using of a permanent catheter in old men with prostatic disease.

One method used as a substitute for the suprapubic cystostomy in emergency cases is the puncture with a trocar above the pubis. This is not without danger in the hands of some surgeons, to say the least, and it does not in any way shorten the major operation.

My chief argument, however, is that by doing a preliminary suprapubic cystostomy we accomplish everything that any of the other methods do; we are able to do it under a local anæsthetic; we have exposed the suprapubic tissues to infection and, if this takes place, which is a very rare occurrence in these cases, it may be overcome and will subside before enucleation of the prostate is undertaken. Again, as the result of the preliminary cystostomy, the œdema and swelling around the neck of the bladder, including the prostate, greatly diminish. I have seen the prostate diminish one-half in size after the suprapubic cystostomy alone. This is of advantage in the enucleation and the healing of the wound.

V. THE TECHNIC OF TRANSVESICAL PROSTATECTOMY.

When it has been proven to the surgeon's satisfaction that the prostate can be safely removed, judging from the functional test of the kidney compared with the original functional test and taking into account the amount of urea excreted and the evidences of acute or chronic renal disease, as well as the general condition of the patient, as previously stated, the operation may be undertaken. The patient is prepared as for any other operation. When the dressings are removed, after

FIG. 33.

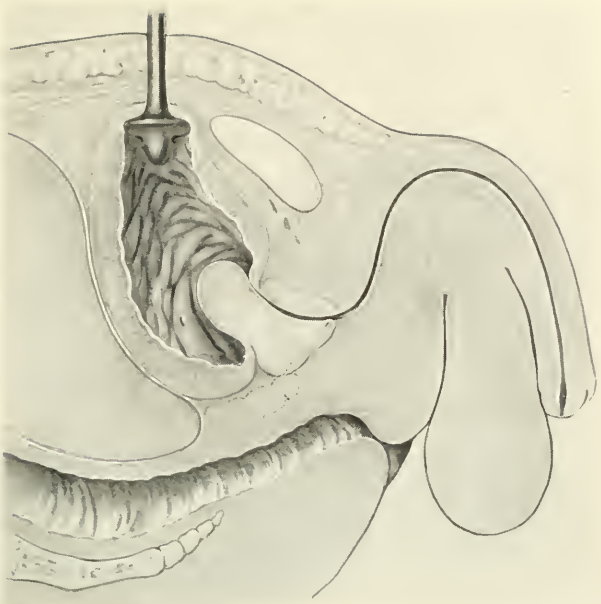

Pezzer catheter in place after suprapubic cystostomy. Button of the catheter fits snugly and is far superior to the ordinary drainage tube inasmuch as it does not permit any rough or sharp surface to irritate the prostate or the bladder wall. This idea was first suggested to me by Rovsing and is the method which he follows.

FIG. 34.

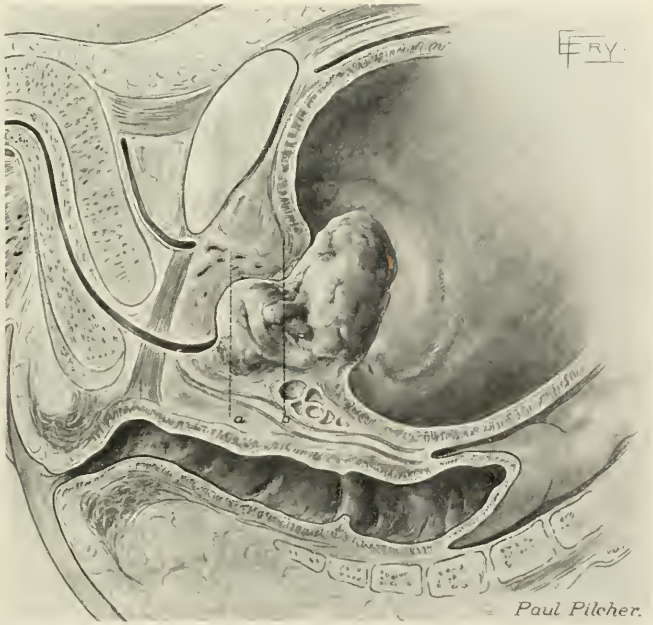

The surgical problem. The picture presented illustrates the average case of prostatic hypertrophy with a special development of the median lobe. It is shown to emphasize the bearing of the surgical pathology upon the choice of method of operation.

FIG. 35.

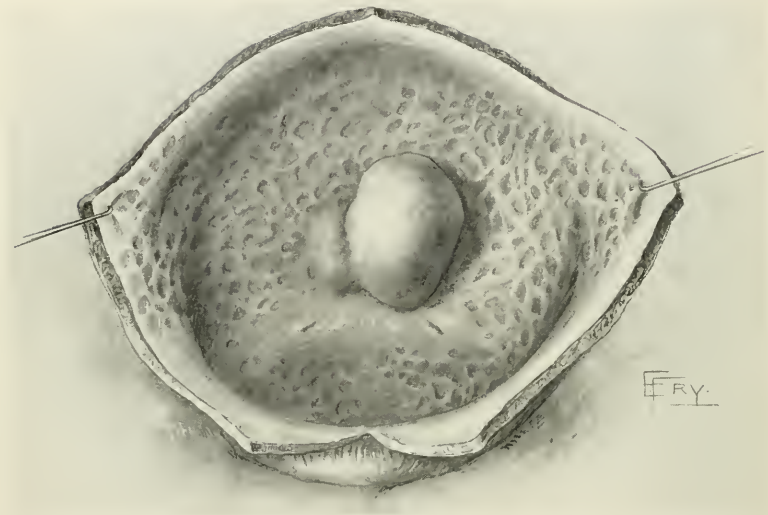

Illustrates a second view of the vesical aspect of a hypertrophied prostate showing the irregularity of the outgrowth and emphasizing the fact that the prostatic hypertrophy is a lesion of the bladder and not of the perineum.

the preliminary cystostomy using the Pezzer catheter, it will be found that the wound surrounding the catheter has healed by primary union. *The silk sutures are still in place. These are not removed,* for they are needed to hold together the recent wound while the finger is enucleating the prostate.

First step: The skin is prepared with iodine. The Pezzer catheter is removed and the *gloved finger* introduced into the

FIG. 36.

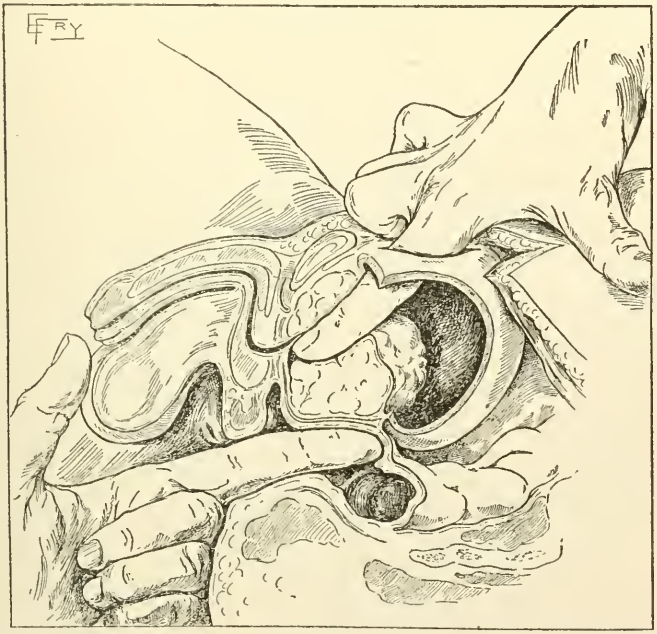

Transvesical prostatectomy. Enucleation of the prostate. Usual method. Finger is introduced into the urethra and advanced as far as possible before breaking through the urethral mucous membrane. Usually the line of cleavage is easily found from the urethra and the enucleation is accomplished as described in the text.

bladder through the suprapubic opening. This opening easily dilates sufficiently to allow free manipulation of the finger. The index finger of the other hand is introduced into the rectum and the prostate is lifted up.

Second step: Enucleation of the prostate. The index finger of the enucleating hand is introduced into the prostatic urethra and advanced as far as possible, reaching, if possible, the furthest point of the prostatic enlargement. This method,

as shown in Fig. 36, is especially useful in two forms of prostatic enlargement, that which is due to an irregular enlargement of both lateral lobes, and that which is due to enlargement of both lateral lobes and the median lobe, even though the median lobe be enlarged out of all proportion to the other two lobes, as in Fig. 3. With the finger in the prostatic urethra, the point of least resistance in the mucous membrane of the urethra is sought. Usually this will be found on the lateral or the antero-

FIG. 37.

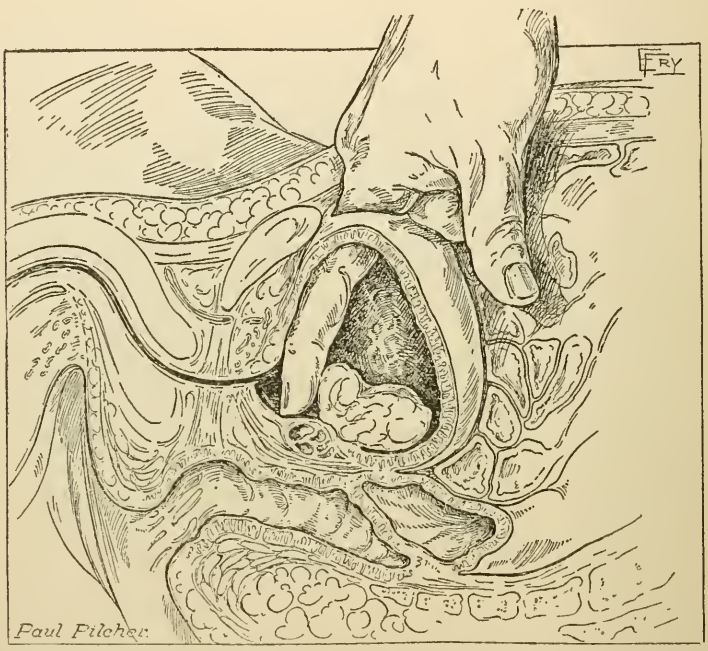

Drawing illustrating one of the final steps in enucleation of the prostate. The lateral lobes have been freed and the mass together with the median lobe is being turned over and turned into the bladder, stripping up the mucous membrane of the bladder from the surface of the prostate.

lateral wall of the urethra. At this point the division between the prostate and the urethra is usually quite easily broken through. In all of my recent cases I have been able to gain the line of cleavage through the urethra easily with the gloved finger. The finger after entering the line of cleavage sweeps, first, slowly around the distal portion of the growth, and then, up over the anterior surface of the growth separating it from

FIG. 38.

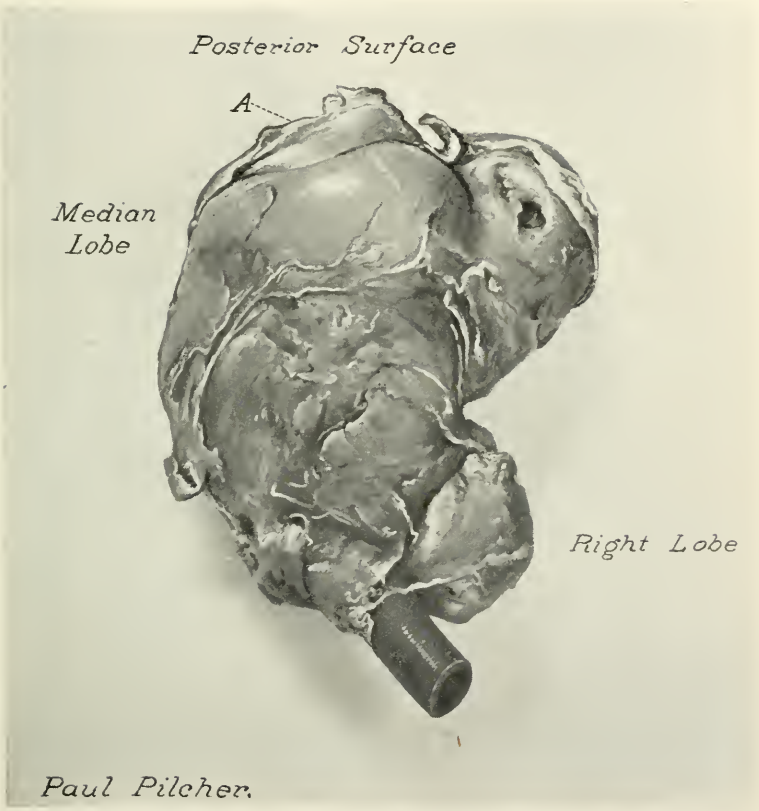

Under surface of prostatic mass showing the enormous median lobe and the small right lobe. "*A*" shows the torn edges of the mucous membrane stripped up from posterior surface.

Fig. 40.

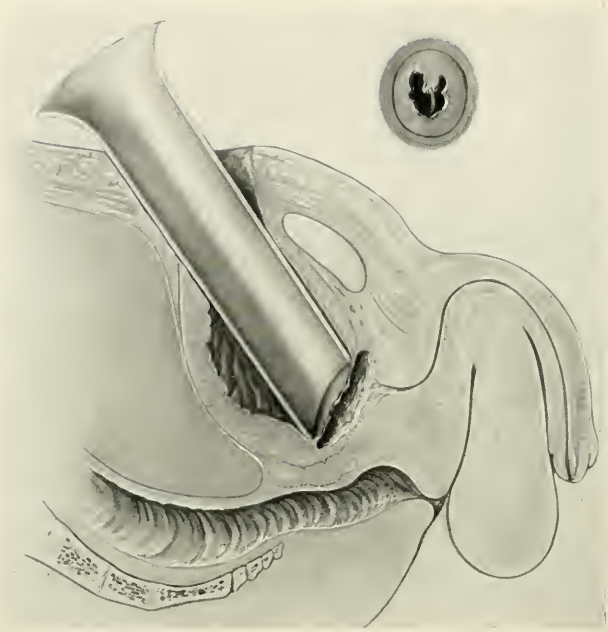

Illustrating the method used by Fenwick to control hemorrhage after prostate had been removed. Small picture in upper right hand corner shows condition frequently found for a small blood-vessel which seemed to be bleeding, contained in the torn edges of the bladder mucous membrane. Illustration shows the speculum in place with the neck of the bladder exposed, that the operator may directly clamp any bleeding vessel. This method in the hands of Fenwick is ideal.

the prevesical tissue. The finger is then passed across the urethra to the other side with a sweeping motion of the finger and the opposite lateral lobe is freed. Then passing the finger up over the entire mass an attempt is made to turn the growth over so that it will easily turn out into the bladder carrying with it the median lobe (Fig. 37). That is to say, the finger is passed up over the two loosened lateral lobes and then beneath the same between the enlarged lobes and the rectum, and then

FIG. 39.

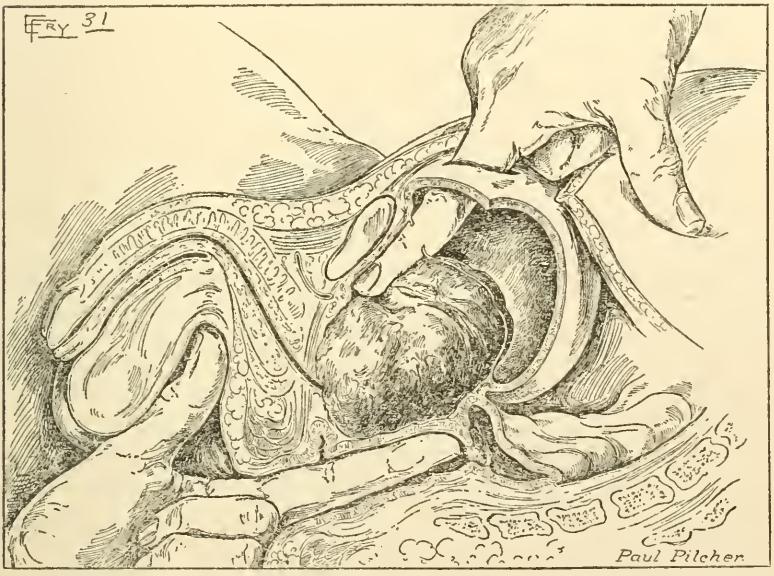

Drawing illustrating method of removing a massive hypertrophy of the prostate where the urethral enucleation is impracticable. This is applicable in the large bilateral hypertrophies. The illustration shows the finger raising up the sphincter, enucleating the prostatic mass in one piece.

the finger is pulled toward the bladder so that the growth will turn upon itself, as is shown more clearly in Fig. 37.

As the growth is turned out into the bladder, the bladder mucous membrane will be stripped up from the posterior side of it, as may be seen in Fig. 38. The point which is most difficult to free is the attachment at the junction of the prostatic and membranous urethra, which is seemingly a fibrous attachment, or may be the attachment to the atrophied posterior lobe which lies distal to the ejaculatory ducts and which prob-

ably is not removed in the majority of cases. It has been our experience that *those cases in which the prostate does not shell out easily should be carefully examined for evidences of malignancy.*

The other type of prostate which is occasionally met with is the enormous prostate which seems to be hypertrophied in all its parts with the exception of the median lobe. Such a prostate is seen in Fig. 12. In removing this prostate it may often be more completely and more easily done by passing the finger between the sphincter vesicæ and the growth itself and sweeping the finger around the growth, as recommended by Freyer. It will quickly fall out into the bladder. This method of enucleation is illustrated in Fig. 39. However, in the majority of cases the intra-urethral enucleation is to be preferred. It is quite essential for the welfare of the patient that all of the prostate as far as possible shall be removed. Thus, Fig. 6 shows a prostate with a very large median lobe and two moderately enlarged lateral lobes, with many pieces of prostatic tissue which were dug out from the capsule after the main growth had been removed. The operator should never be satisfied with removing the larger adenomatous mass alone, but an attempt should be made to bring away all the prostatic tissue possible unless there is a diffuse carcinomatous involvement. If fragments remain, they retard the healing of the cavity from which the prostate has been removed and are apt to necrose and cause a delay in the healing of the bladder.

Third step: Removing the prostatic sections and the blood clots from the bladder. A pair of forceps is passed through the suprapubic wound and the pieces of prostate which have been turned out from the bladder are carefully removed. All of the blood clots in the bladder should be washed out so that no pieces of foreign material are left behind.

Control of the Hemorrhage.—A number of methods have been devised for controlling the hemorrhage.

First, the Fenwick method by clamp and ligature. Fenwick has devised a series of three specula of different sizes which may be introduced through the suprapubic wound, bringing

the area from which the prostate has been removed directly into view. The use of one of these speculum is illustrated in Fig. 40. The headlight is used to illuminate the cavity. With the lacerated oozing area in view and properly illuminated, the area is sponged as dry as possible and it will be found, as a rule, that *bleeding does not come so much from the cavity from which the prostate has been removed, but usually from the free edges of the lacerated tissue* which covers the surface of the prostate on its vesical aspect. This was very beautifully demonstrated to the writer by Mr. Fenwick himself. In one case he was able to show me a spurting vessel in this free edge. He demonstrated further that the area from which the prostate has been removed flattens out very quickly and does not remain as a cavity, but retracts down and, as a rule, does not allow space for the accumulation of blood clots. Through the speculum the bleeding points are caught with specially devised hæmostats. In this way, as a rule, the bleeding can be entirely controlled. In most cases after a few minutes crushing with the hæmostats they may be removed and no further bleeding will occur. The hæmostats are so constructed that the handles may be removed, if necessary, and left *in situ* for 24 hours.

As a modification of this method, the writer would suggest the use of the actual cautery through the speculum to control any bleeding point which might come into view.

Second, control by suture. A number of prominent operators complete their prostatectomies by surrounding the area from which the prostate has been removed by a continuous catgut suture. This necessitates a large suprapubic wound and consumes considerable time and, in the experience of the writer, has never been found necessary.

Third, control by pressure. With one finger in the rectum and a finger in the bladder the tissues involved in the prostatic wound may be pressed together and in this way much oozing will be prevented. At the last meeting of the American Urological Society in Boston, April, 1913, the writer presented a method of controlling hemorrhage, using gauze packing.[4]

[4] Pilcher: *Transactions of the American Urol. Soc.*, 1913, vol. vii, p. 57.

This consists of introducing a catheter through the urethra which serves as a guide and centre around which the packing is to be placed. Then a narrow strip of gauze packing is introduced through the suprapubic wound and the torn edges of mucous membrane which have been stripped up from the prostate are pressed down into the shallow prostatic pouch and held in place by gauze packing, as is shown in Figure 41. This shows the prostatic pouch exaggerated with the torn flaps of mucous membrane pushed before the gauze packing and in addition the Pezzer catheter used to hold the gauze packing in place. This Pezzer catheter may be introduced by first passing a silver catheter through the urethra and out from the suprapubic wound and then attaching the small end of the Pezzer catheter to the silver catheter and drawing it out through the urethra. With the expanded end of the catheter on the vesical side of the packing, considerable pressure may be brought to bear, using a very small amount of gauze packing by pulling on the penile end of the catheter. Up to the present time we have always used the simple rubber catheter as a guide and centre around which to pack the gauze. The end of the gauze is led out through the abdominal wound (Fig. 41). Other methods of controlling hemorrhage by direct pressure have been devised, but none of them are superior to those which have been mentioned.

Control of Secondary Hemorrhage from the Bladder.—Hemorrhages occurring within 12 to 24 hours after the prostatectomy are best controlled by packing the prostatic pouch around a catheter introduced through the urethra. In one case the writer passed a silk suture through the perineum, placed a gauze packing over the prostatic pouch and fastened the silk suture to this gauze packing, tying the same on the outside of the perineum. *Secondary hemorrhage which occurs a week or so after the operation* may be either from the wound itself which calls for re-opening the wound and suture, or may be from the vesical neck or the prostatic pouch itself. Such an occurrence calls for re-opening of the bladder, exposure of the bleeding point and securing same either by suture, the actual

FIG. 41.

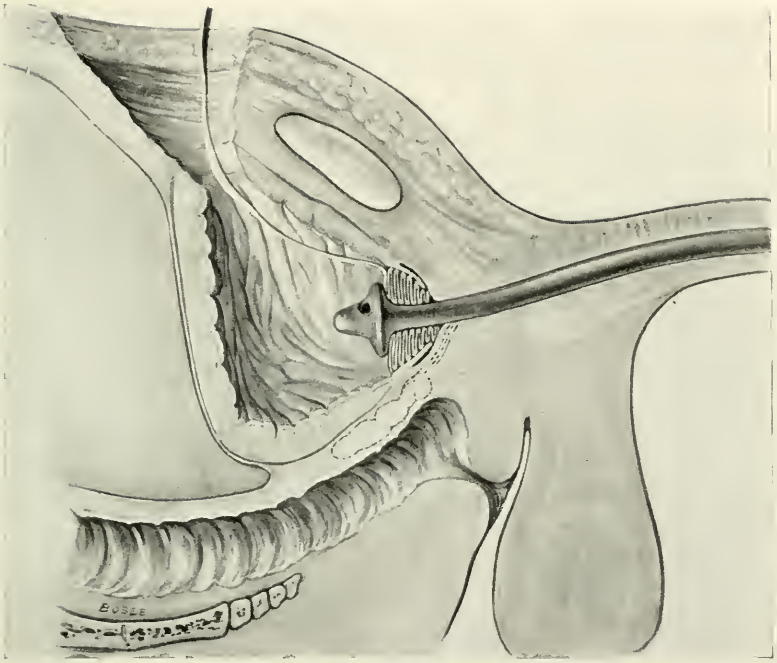

Showing method of controlling hemorrhage by the use of packing. The Pezzer catheter is introduced by first passing a silver catheter through the urethra and out through the suprapubic wound attaching the Pezzer catheter to the silver catheter and withdrawing same through the urethra. When the Pezzer catheter is in place, the packing is inserted, consisting of narrow gauze, introducing it in such a way that the torn mucous membrane flaps of the bladder are pushed ahead of the packing and when the packing is in place the Pezzer catheter is pulled down, keeping the packing in place and exerting pressure against the bleeding surface at the same time. In order to hold the Pezzer catheter firmly in place, it should be attached to the leg by adhesive plaster. The gauze is removed after 24 hours and the catheter at will.

FIG. 42.

Appearance of suprapubic scar two weeks after the operation. It is meant especially to show the clean appearance of the wound which is entirely free of incrustations or sloughs.

cautery or the high-frequency spark generated from the D'Arsonval current. In one case of my own, it was necessary after the second week to re-open the bladder widely and cauterize the entire area of the vesical neck before the hemorrhage could be stopped.

Drainage of the Bladder After Transvesical Prostatectomy.—To the mind of the writer, it is very *essential to drain the bladder suprapubically after every case of prostatectomy.* We consider it dangerous and unnecessary to run the risk of closing the bladder after transvesical prostatectomy. This has been emphasized in our own experience in two cases in which we closed the bladder and were compelled to re-open and drain the bladder on account of severe hemorrhage within the bladder which clogged the urethral catheter. Our routine is, as soon as the prostate is removed and the hemorrhage checked, to introduce a large rubber drainage tube, one inch in diameter, just within the wall of the bladder, and after securing it in place to apply copious gauze dressings over the same. If the packing of the prostatic pouch is necessary, a small gauze packing is brought out through the large drainage tube. It should be emphasized at this point that none of the silk skin sutures introduced at the primary operation have been removed, and that after the enucleation of the prostate no suturing of the wound is necessary. The cystostomy wound made at the first operation is capable of very great distention without tearing it open if the original sutures have not been removed.

After-treatment.—As soon as the patient has been returned to his bed a proctoclysis of tap water is begun and the abdominal dressings changed as frequently as necessary. *After 24 hours* the bladder is irrigated through the suprapubic tube which is still in place. If packing is in place it is removed, together with the large suprapubic drainage tube. The Pezzer catheter replaces the suprapubic drainage tube. It will be found that in six to eight hours the bladder wall will contract around the Pezzer catheter and very little urine will leak out beside it. The Pezzer catheter is left in place for three or four days until the wound surfaces have healed over. This tends to pre-

vent the formation of sloughs and phosphatic concretions on the wound surfaces (Fig. 42). Also, the use of drugs to prevent alkalinity of the urine will tend to give a better wound. *On the fourth or fifth day* the Pezzer catheter is removed and is replaced by a collecting device of an English maker, which is shown in Fig. 43. The wound is strapped with a piece of inch-wide adhesive tape and what urine escapes is

Fig. 43.

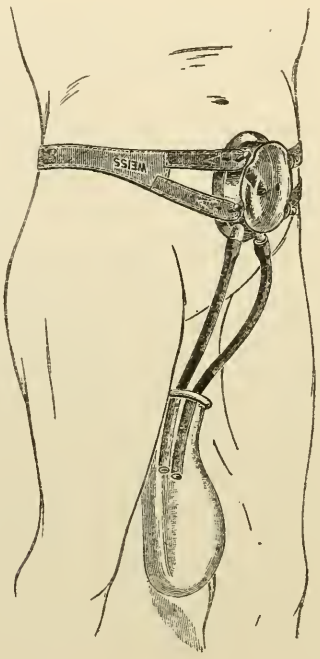

collected in the celluloid cup and drains from the cup into a bottle through a rubber tube. This ingenious device is held in place by rubber straps which keep it from slipping. It is a very convenient and comfortable adjunct to the convalescence. If the suprapubic cup is not available, the use merely of masses of absorbent gauze over the fistula will answer any need until the fistula closes and normal urethral urination is re-established.

The period of healing of the suprapubic wound has in our experience taken from one week to four weeks, *the average be-*

ing about 16 days. In none of our cases has there been any permanent suprapubic fistula. The nearest approach to it was in the case of recurrent secondary hemorrhage in which the bladder was twice widely opened in order to control the hemorrhage. In one case the suprapubic wound closed in four days.

Control of the Urine.—About the eighth to tenth day, as a rule, small amounts of urine will pass *per urethram,* the amount increasing as the suprapubic wound contracts. It is worthy of note that in none of our recent cases has dribbling been noticed, and that within two or three weeks after the operation the patients have fairly good control, and in all the cases operated upon by us after this method the result has been full control of the urine with complete emptying of the bladder.

Potency of the Male.—This operation does not seem to interfere with the functions of the ejaculatory ducts, in fact, in a number of instances the potency has increased as a result of the operation.

CONCLUSIONS.

Studies of the living pathology of chronic prostatism lead us to the conclusion that obstructive prostatic hypertrophy usually involves the two lateral lobes and the median lobe, and that inasmuch as the obstruction is at the neck of the bladder and the obstructing body projects into the bladder, the natural avenue of approach is the transvesical route.

Second, as a result of relieving the distention of the bladder, three phases of kidney secretion are demonstrable; the second phase, lasting from a few days to a number of weeks, constitutes a period of danger during which no surgical attack should be undertaken.

Third, the technic advocated in the present paper includes a two-step transvesical operation in every instance for the relief of benign hypertrophy of the prostate. Preliminary cystostomy is preferred for the reason that, following the suprapubic cystostomy the patient is out of bed in 24 hours; the urinary output from the bladder is completely controlled; there is no unpleasantness or traumatism due to the passage of

the catheter through the urethra, and the operation of transvesical prostatectomy is already half completed.

Fourth, since applying these principles we are able to report to date 28 successive successful cases, every case resulting in the control of urine by the patient and his ability to empty the bladder without using a catheter. In some cases of enormous distention of the bladder, it is necessary to catheterize for a certain length of time before employing suprapubic cystostomy on account of the extreme back pressure on the kidneys, the sudden decompression of which might result fatally.

Fifth, these same rules do not apply in cases where carcinoma of the prostate has been diagnosed, or even where its presence is fairly well suspected. A later communication will deal with this part of the subject.

REFERENCES.

Pilcher: Obstructive Hypertrophy of the Prostate Body. ANNALS OF SURGERY, vol. xli, p. 481, April, 1905.

Tandler and Zuckerkandl: Folia Urologica Internationales Archiv für die Krankheiten der Harnorgane, March, 1911.

Lowsley: Jour. A. M. A., January 11, 1913, page 110.

Wilson and McGrath: Surgical Pathology of the Prostate. Surg. Gyn. and Obs., December, 1911, p. 647–681.

Squier, J. Bentley: Vital Statistics of Prostatectomy. Surg., Gyn. and Obs., vol. 17, No. 4, page 433.

Albarran: Maladies de la Prostate, 1902, page 546.

Watson, F. S.: Operative Treatment of the Hypertrophied Prostate, 1888.

Wade, H.: Prostatism. The Surgical Anatomy and Pathology of the Operative Treatment. ANNALS OF SURGERY, March, 1914, vol. lix, No. 3, page 321.

COLUMBIA UNIVERSITY LIBRARIES

This book is due on the date indicated below, or at the expiration of a definite period after the date of borrowing, as provided by the rules of the Library or by special arrangement with the Librarian in charge.

DATE BORROWED	DATE DUE	DATE BORROWED	DATE DUE
C28(1141)M100			

RD587

Pilcher P64

Transvesical prostatectomy in two stages.

2-30-1/3 C. H. Bindery

COLUMBIA UNIVERSITY LIBRARIES (hsl,stx)
RD 587 P64 C.1
Transvesical prostatectomy in two stages
2002434156